



Plasmapheresis effectively abrogates severe liver toxicity of pegaspargase in a patient with acute lymphoblastic leukemia

Markus Tölle¹ · Nicola Gökbüget^{2,3} · Stefan Habringer^{4,5} · Ulrich Keller^{4,5} · Stefan Schwartz^{4,5}

Received: 31 March 2024 / Accepted: 2 May 2024
© The Author(s) 2024

Dear Editor,

Asparaginase is an essential component in the treatment of acute lymphoblastic leukemia (ALL) and its use has been intensified in recent years in treatment protocols across all age groups [1]. Various formulations are available and among these, pegaspargase, a pegylated, *E. coli*-derived asparaginase, offers a long half-life requiring less frequent dosing together with a lower risk of antibody formation and hypersensitivity reactions [2]. However, the management of pegaspargase-related toxicities might be challenging beyond drug administration due to its pharmacokinetic properties.

A 57-year-old male with common ALL received consolidation therapy with high-dose methotrexate (days 1 and 15: 1 g/m²) and pegaspargase (days 2 and 16: 1,000 units/m²) within a trial evaluating an age-adapted treatment protocol (ClinicalTrials.gov, NCT 03480438, March 21 2018) [3]. The liver function tests (LFTs) slightly increased on day

11 (alkaline phosphatase 1.3x upper limit of normal). Upon further increase of LFTs, ursodeoxycholate was started on day 16 (250 mg qid), but LFTs rapidly increased further (maximum alkaline phosphatase: 13x upper limit of normal). In addition, a high asparaginase activity in the serum was measured on day 27 (642 U/L). Therefore, the decision was made to eliminate asparaginase from the circulation by plasmapheresis. On days 28–30, the patient underwent three sessions with a treated plasma volume of 1.0–1.2 of the calculated total plasma volume, which was replaced by an isotonic albumin solution. The result of this intervention was an immediate decrease of the asparaginase activity down to zero and a rapid and sustained normalisation of LFTs (Fig. 1). The antineoplastic treatment was resumed on day 42, which represents a delay of the scheduled therapy of only 6 days. At present, the patient is in continuous, complete molecular remission of his ALL while receiving maintenance therapy.

Toxicities of asparaginase could affect a variety of organ systems, including the liver, and might be severe and prolonged after pegaspargase. However, extracorporeal drug removal has not been included into proposed treatment algorithms of asparaginase toxicities [4]. Only two patients treated with plasmapheresis for asparaginase liver toxicity have been reported [5, 6]. One patient had received a total dose of 3,750 units pegaspargase, whereas the other patient was treated with 5,000 units/m² daily of non-pegylated L-asparaginase over 14 days. Both patients improved with plasmapheresis, but the asparaginase activity was not or incompletely monitored. Thus, it remains unclear whether the observed improvements represent a spontaneous course or were due to removal of asparaginase. In our patient, the liver toxicity correlated closely with a high asparaginase activity and rapidly vanished with asparaginase removal and decrease of the enzyme activity down to zero. We therefore advocate that plasmapheresis should be integrated into the treatment algorithms of severe asparaginase toxicities.

✉ Stefan Schwartz
stefan.schwartz@charite.de

- ¹ Department of Nephrology and Medical Intensive Care (Campus Benjamin Franklin), Charité – Universitätsmedizin Berlin, corporate member of Freie Universität and Humboldt-Universität zu Berlin, Hindenburgdamm 30, 12203 Berlin, Germany
- ² Medizinische Klinik II, Universitätsklinikum der Johann-Wolfgang-Goethe Universität, Theodor-Stern-Kai 7, 60596 Frankfurt/Main, Germany
- ³ German Cancer Consortium (DKTK), partner site Frankfurt/Mainz, a partnership between DKFZ and Johann-Wolfgang-Goethe Universität, 60596 Frankfurt/Main, Germany
- ⁴ Department of Hematology, Oncology and Cancer Immunology (Campus Benjamin Franklin), Charité – Universitätsmedizin Berlin, corporate member of Freie Universität and Humboldt-Universität zu Berlin, Hindenburgdamm 30, 12203, Berlin, Germany
- ⁵ German Cancer Consortium (DKTK), partner site Berlin, a partnership between DKFZ and Charité-Universitätsmedizin Berlin, 12203 Berlin, Germany

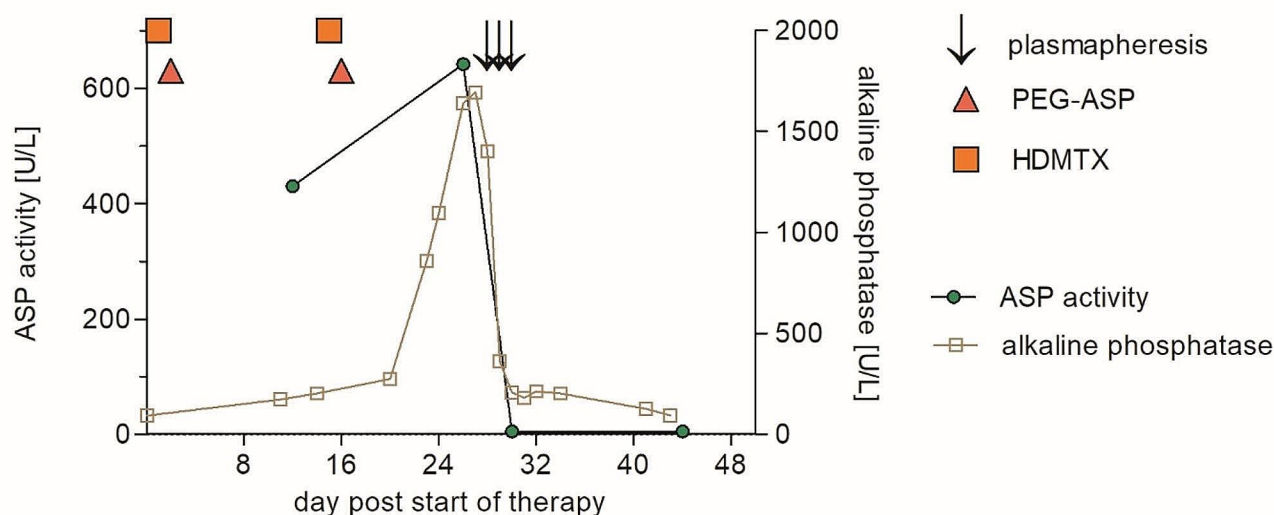


Fig. 1 Clinical course of a patient with acute lymphoblastic leukemia and pegaspargase toxicity. Following consolidation therapy with high-dose methotrexate (HDMTX) and pegaspargase (PEG-ASP) severe

liver toxicity occurred in association with high asparaginase (ASP) activity, which vanished with pegaspargase removal by plasmapheresis

Author contributions M.T., N.G., S.H., U.K. and S.S. contributed to the treatment conception and design. Data collection and analysis were performed by all authors. The first draft of the manuscript was written by M.T. and S.S., and all authors commented on all versions of the manuscript. All authors read and approved the final manuscript.

Funding The authors did not receive support from any organization for the submitted work.

Open Access funding enabled and organized by Projekt DEAL.

Data availability No datasets were generated or analysed during the current study.

Declarations

Disclosure of potential conflicts of interest The authors have no competing interests to declare related to the content of this article. MT has received research grants from 3RNetzwerk, Baxter, Deutsche Forschungsgemeinschaft, Bundesministerium für Wissenschaft und Forschung, consulting fees from Boehringer Ingelheim, honoraria from AstraZeneca, Bayer, Boehringer Ingelheim, Deutsche Gesellschaft für Kardiologie, Deutsche Hochdruckliga, Medical Tribune, MedPoint, Novartis, Sanofi, and fees as a data safety or advisory board member from Boehringer Ingelheim unrelated to this article. NG has received honoraria from Clinigen, Jazz Pharmaceuticals, Servier, and fees as a data safety or advisory board member from Clinigen, Jazz Pharmaceuticals, Servier, unrelated to this article. SH has received travel grants from Sanofi, fees as a data safety or advisory board member from Incyte, Pentixapharm, and is co-founder of the Moonlight AI GmbH, unrelated to this article. UK has received travel grants from Janssen-Cilag, Roche, and research grants from Exscientia Inc., unrelated to this article. SS has received consulting fees from AMGEN, Gilead, Pfizer, Resonance Inc., SERB SAS, honoraria from Akademie für Infektionsmedizin, AMGEN, AvirPharma, CSi Hamburg, Labor28, SERB SAS, Pfizer, travel grants from AMGEN, Gilead, Pfizer, SERB SAS, and fees as a data safety or advisory board member from AMGEN, Gilead, Pfizer, SERB SAS, unrelated to this article.

Informed consent and ethics approval Written informed consent was obtained from the patient for the publication of this case report. Ethical approval for the report of cases is not required by the national regulations or the Charité – Universitätsmedizin Berlin.

Open Access This article is licensed under a Creative Commons Attribution 4.0 International License, which permits use, sharing, adaptation, distribution and reproduction in any medium or format, as long as you give appropriate credit to the original author(s) and the source, provide a link to the Creative Commons licence, and indicate if changes were made. The images or other third party material in this article are included in the article's Creative Commons licence, unless indicated otherwise in a credit line to the material. If material is not included in the article's Creative Commons licence and your intended use is not permitted by statutory regulation or exceeds the permitted use, you will need to obtain permission directly from the copyright holder. To view a copy of this licence, visit <http://creativecommons.org/licenses/by/4.0/>.

References

1. Douer D, Gokbuget N, Stock W, Boissel N (2022) Optimizing use of L-asparaginase-based treatment of adults with acute lymphoblastic leukemia. *Blood Rev* 53:100908. <https://doi.org/10.1016/j.blre.2021.100908>
2. Juluri KR, Siu C, Cassaday RD (2022) Asparaginase in the treatment of Acute lymphoblastic leukemia in adults: current evidence and place in Therapy. *Blood Lymphat Cancer* 12:55–79. <https://doi.org/10.2147/BLCTT.S342052>
3. Goekbuget N, Schwartz S, Faul C, Topp MS, Subklewe M, Renzelmann A, Stoltefuss A, Hertenstein B, Wilke A, Raffel S, Jäkel N, Vucinic V, Niemann DM, Reiser L, Serve H, Brüggemann M, Viardot A (2023) Dose reduced chemotherapy in sequence with Blinatumomab for newly diagnosed older patients with Ph/BCR::ABL negative B-Precursor adult lymphoblastic leukemia (ALL): preliminary results of the GMALL bold trial.

- Blood 142(Supplement 1):964–964. <https://doi.org/10.1182/blood-2023-180472>
4. Pourhassan H, Douer D, Pullarkat V, Aldoss I (2023) Asparaginase: how to better manage toxicities in adults. *Curr Oncol Rep* 25(1):51–61. <https://doi.org/10.1007/s11912-022-01345-6>
 5. Bilgir O, Calan M, Bilgir F, Cagliyan G, Arslan O (2013) An experience with plasma exchange treatment of acute lymphoblastic leukemia in a case with fulminant hepatitis related to L-asparaginase. *Transfus Apher Sci* 49(2):328–330. <https://doi.org/10.1016/j.transci.2013.06.010>
 6. Gopel W, Schnetzke U, Hochhaus A, Scholl S (2016) Functional acute liver failure after treatment with pegylated asparaginase in a patient with acute lymphoblastic leukemia: potential impact of plasmapheresis. *Ann Hematol* 95(11):1899–1901. <https://doi.org/10.1007/s00277-016-2773-0>

Publisher's Note Springer Nature remains neutral with regard to jurisdictional claims in published maps and institutional affiliations.