

# Clinical Characterization and Ancillary Tests in Susac Syndrome

## A Systematic Review

Adi Wilf-Yarkoni, MD, BSc,\* Ofir Zmira, MD,\* Assaf Tolkovsky, MD, Barak Pflantzer, MD, Shany G. Gofrit, MD, Ilka Kleffner, MD, Friedemann Paul, MD, and Jan Dörr, MD

**Correspondence**  
Dr. Wilf-Yarkoni  
adi.wilf@gmail.com

*Neurol Neuroimmunol Neuroinflamm* 2024;11:e200209. doi:10.1212/NXI.000000000200209

## Abstract

Susac syndrome (SuS) is an orphan microangiopathic disease characterized by a triad of encephalopathy, visual disturbances due to branch retinal artery occlusions, and sensorineuronal hearing loss. Our previous systematic review on all cases of SuS reported until 2012 allowed for a better understanding of clinical presentation and diagnostic findings. Based on these data, we suggested diagnostic criteria in 2016 to allow early diagnosis and treatment of SuS. In view of the accumulation of new SuS cases reported in the last 10 years and improved diagnostic tools, we here aimed at updating the demographic and clinical features of SuS and to review the updated ancillary tests being used for SuS diagnosis. Therefore, based on the 2016 criteria, we systematically collected and evaluated data on SuS published from January 2013 to March 2022.

## Introduction

Susac syndrome (SuS), first described in 1979 by J. Susac,<sup>1</sup> is a microangiopathic multiorgan disease characterized by encephalopathy, visual disturbances due to branch retinal artery occlusions (BRAOs), and sensorineuronal hearing loss (SNHL). The presence of serum anti-endothelial antibodies in some but not all patients with SuS,<sup>2,3</sup> and pathology findings, including mononuclear cells in perivascular spaces, basal membrane thickening,<sup>4</sup> and perivascular inflammation and narrowing,<sup>5</sup> suggest an autoimmune etiology. The disease affects mainly women in their 30s.<sup>6,7</sup> Treatment is tailored according to CNS disease severity and should always include glucocorticosteroids, often in combination with other immunomodulation or immunosuppression, including IV immunoglobulins (IVIG), cyclophosphamide, mycophenolate mofetil, and rituximab.<sup>8,9</sup> Relevant residua after treatment and disease recurrence are both well described.<sup>10</sup>

Although rare, SuS is a disease entity which can be readily encountered and a great mimicker of other diseases. It may be incorrectly diagnosed as CNS infection, malignancy, and a variety of other autoimmune diseases, such as limbic encephalitis, vasculitis, multiple sclerosis (MS), Bechet disease, and systemic lupus erythematosus.<sup>8</sup> Early diagnosis and treatment are crucial for improved outcome.<sup>9</sup>

The diagnosis of SuS is in particular based on a constellation of clinical and laboratory findings. In 2016, we suggested diagnostic criteria, to allow a homogenous language among clinicians and to facilitate early diagnosis and treatment.<sup>11</sup> According to these criteria, patients are differentiated based on the diagnostic security into “definite SuS,” “probable SuS,” and patients in which the diagnosis of

\*These authors contributed equally to this manuscript.

From the Department of Neurology (A.W.-Y., A.T.), Rabin Medical Center, Petah Tikva; Department of Neurology and Neurosurgery (A.W.-Y., A.T., B.P., S.G.G.), Sackler Faculty of Medicine, Tel Aviv University; Department of Neurology (O.Z.), Hillel Yaffe Medical Center, Hadera; Department of Neurology (O.Z.), Ruth and Bruce Rappaport Faculty of Medicine, Technion Institute of Technology, Haifa; Department of Neurology (B.P., S.G.G.), Sheba Medical Center, Ramat Gan, Israel; Department of Neurology (I.K.), University Hospital Knappschaftskrankenhaus Bochum, Ruhr University Bochum; Experimental and Clinical Research Center (F.P., J.D.), Max Delbrueck Center for Molecular Medicine and Charité Universitätsmedizin Berlin; and Multiple Sclerosis Center (J.D.), Neurology Department, Oberhavel Kliniken, Hennigsdorf, Germany.

Go to [Neurology.org/NN](https://www.neurology.org/NN) for full disclosures. Funding information is provided at the end of the article.

The Article Processing Charge was funded by the authors.

This is an open access article distributed under the terms of the Creative Commons Attribution-NonCommercial-NoDerivatives License 4.0 (CC BY-NC-ND), which permits downloading and sharing the work provided it is properly cited. The work cannot be changed in any way or used commercially without permission from the journal.

## Glossary

**AECA** = antiendothelial cell antibodies; **AWH** = arterial wall hyperfluorescence; **BRAO** = branch retinal artery occlusion; **DA-FA** = disease activity-FA; **FA** = fluorescein angiography; **IVIG** = IV immunoglobulins; **MS** = multiple sclerosis; **OCT** = optical coherence tomography; **OCT-A** = OCT-angiography; **SNHL** = sensorineuronal hearing loss; **SuS** = Susac syndrome; **UWF** = ultra-widefield.

SuS is not the most probable. To be diagnosed with definite SuS, patients must meet all 3 of the following criteria: brain involvement such as new cognitive impairment, behavioral changes, new focal neurologic symptoms, or headache, in the presence of typical MRI findings; symptomatic or asymptomatic retinal involvement, including BRAO or arterial wall hyperfluorescence on fluorescein angiography; vestibulocochlear involvement, including tinnitus, hearing loss, or vertigo, accompanied by findings such as a pathologic audiogram and caloric testing. Probable SuS includes patients fulfilling only 2 criteria out of the 3.<sup>11</sup> It is important to remember that SuS is a rare disease, and the clinical and MRI findings may mimic other more common diseases such as inflammatory demyelinating disease (MS), cerebrovascular disease, vasculitis, infections, and malignancy. These disorders must be ruled out before making the diagnosis of SuS, especially when the criteria are not fully met.

Knowledge regarding its epidemiology, pathogenesis, and treatment is accumulating but is still based mainly on reports of single cases or small case series.

Our previous systematic review on all cases of SuS reported until end of 2012 allowed for better understanding of clinical presentation and diagnostic findings.<sup>6</sup> Considering the Kleffner criteria, alongside the accumulation of new SuS cases reported in the last 10 years and improved diagnostic tools, we aimed at updating the knowledge on SuS. Therefore, we systematically collected and evaluated data on SuS published from January 2013 to March 2022.

## Methods

### Search Strategy

In March 2022, a literature search was conducted in PubMed, Embase, and Cochrane in accordance with the PRISMA guidelines.<sup>12</sup> The following search terms were used: “Susac syndrome OR Susac’s syndrome,” “SECRET,” “RED-M,” “microangiopathy AND encephalopathy AND retinopathy,” “Kleffner criteria,” “encephalopathy AND retinal artery occlusion,” “hearing loss AND retinal artery occlusion” (all fields); “brain AND retina AND cochlea,” “retina AND brain AND inner ear,” “microangiopathy AND brain AND retina” (titles/abstracts); “brain AND eye AND ear,” “retinopathy AND encephalopathy” (titles). References of included articles were hand-searched to identify additional articles.

Five reviewers (A.W.Y., O.Z., A.T., B.P., S.G.) independently assessed titles and abstracts according to inclusion and exclusion

criteria, followed by screening of full-text articles. Each full-text article was assessed for eligibility by at least 2 reviewers. In case of disagreement, a third reviewer was consulted.

### Eligibility Criteria

To follow-up on our previous systematic review, articles published between January 2013 and March 2022 were considered.<sup>6</sup> Our previous review included articles published until 12/2012, so overlap between the 2 articles is excluded. Language restrictions were set for English in cases that an accurate translation was not possible. Inclusion criteria were definite or probable diagnosis of SuS according to the criteria published by Kleffner et al.<sup>11</sup>; exclusion criteria were as follows: (1) conference abstracts, (2) case series in which no clear data on demographic and ancillary tests were provided, (3) review articles or letters to editors that did not provide new/original scientific reporting, or (4) restricted access to full article. Whenever authors declared that a patient had already been described in a previous publication, we excluded the respective data to avoid duplication.

## Results and Discussion

### Article Selection

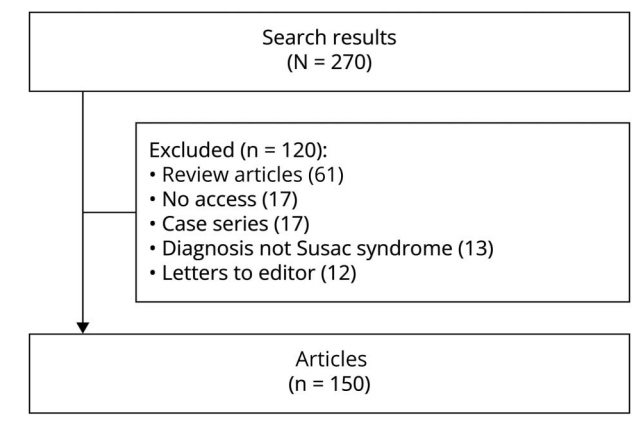
The search yielded in total 270 articles. Excluded were 61 review articles without new relevant data, 12 letters to editors, 17 articles with no access to full-length article, not written in English and impossibility to be translated, and 13 articles in which the final diagnosis was not SuS. Seventeen articles were excluded because of lack of information but were mentioned across the article. Finally, 150 articles were included (Figure 1). Extracted from these 150 articles, a total of 332 individual cases were included in the analyses. Among them, 169 cases were taken from case series, in which some of the data were presented only in averages. In 163 cases, specific features of each patient were described.

### Demographic and Clinical Data

Table 1 summarizes demographic data of our current updated review in comparison with our previous review and a total of the combined cohorts.<sup>6</sup> In the newer cohort, SuS incidence was still higher in female patients with a ratio of 1:1.8, but the female preponderance was lower compared with our previous and other publications.<sup>6,13</sup> This discrepancy may point toward a raising prevalence and/or awareness in male patients. In total of the 2 cohorts, the male:female ratio of the 2 cohorts was 1:2.4.

Similar to the previous cohort, the mean age at disease onset was 29.5 years. The mean length of follow-up was 36.2 months with a

**Figure 1** Flowchart



median of 12 months. Our data suggest predominance of White patients (57%); however, similar to the previous cohort, information on ethnicity was sparsely provided, and there may be misrepresentation of other ethnicities because of publication bias.

Rennebohm et al.<sup>14</sup> suggest empirical stratification of Susac syndrome into 3 major clinical courses, namely monocyclic, polycyclic, and chronic continuous. In our current review, these

courses were hardly reported. It could be due to the short follow-up periods or as a result of a good treatment response.

### SuS Manifestation in the Context of Pregnancy

In 13 patients (3.9%), disease manifestation was during pregnancy, similar to our previous review. This low incidence may imply that pregnancy by itself is not a risk factor. Two of these cases had clinical presentation before pregnancy. In most of the cases, the presentation during pregnancy was mainly subacute encephalopathy manifesting as behavioral changes. This non-specific presentation during pregnancy may mimic other neurologic conditions such as Wernicke encephalopathy secondary to hyperemesis,<sup>15</sup> posterior reversible encephalopathy syndrome,<sup>16</sup> as well as psychiatric conditions. Some autoimmune diseases tend to improve during pregnancy; female patients with dermatomyositis have stable or improving symptoms during pregnancy and postpartum.<sup>17</sup> Future research is needed to evaluate whether that is the case in pregnant patients with SuS. Treatment options and management strategy are discussed in more details in a recently published review of SuS and pregnancy.<sup>18</sup>

### Prior Infection

Prior infection was reported in 17 patients (5.1%) with available data and included 2 cases of HIV infection,<sup>19,20</sup> 2 cases of COVID-19,<sup>21,22</sup> 6 patients with respiratory tract infections,<sup>23-26</sup> 3 with CMV infection,<sup>27</sup> and 1 with gastroenteritis.<sup>28,29</sup> In our

**Table 1** Demographic Data of Patients With Susac Syndrome

Feature	2023 review (N = 332)		2013 review (N = 304)		Total
	Number of cases with available data (% of total cases)	Number of cases (% of available cases)	Number of cases with available data (% of total cases)	Number of cases (% of available cases)	Number of cases (% of available cases)
<b>Sex</b>	331 (99.7)		304 (100)		635
<b>Male</b>		120 (36.2)		67 (22)	187 (29.4)
<b>Female</b>		211 (63.7)		237 (78)	448 (70.5)
<b>M:F ratio</b>		1:1.8		1:3.5	1:2.4
<b>Mean age at disease onset (y)</b>	330 (99.4)	29.5	276 (91)	31.6	30.4
<b>Mean length of follow-up</b>	214 (64.5)	36.2	234 (77)	41	38.7
<b>Median (mo)</b>		12			
<b>Ethnicity</b>	28 (17)		76 (25)		104
<b>White</b>		16 (57)		61 (81)	77 (74)
<b>African-American</b>		1 (3.6)		3 (4)	4 (3.8)
<b>Asian</b>		4 (14.3)		6 (8)	10 (9.6)
<b>Hispanic</b>		3 (10.7)		2 (1)	5 (4.8)
<b>Turkish</b>				4 (5)	4 (3.8)
<b>African</b>		2 (7.1)			2 (1.9)
<b>Afro-Brazilian</b>		1 (3.6)			1 (1)
<b>Pregnancy</b>		13 (3.9)		5%	
<b>Prior infection</b>		17 (5.1)		6.2%	

**Table 2** Clinical Presentation at Disease Onset and During Follow-Up

Symptoms	Manifestation at onset				Manifestation during disease course	
	2023 review (N = 332)		2013 review (N = 304)		2023 review (N = 332)	2013 review (N = 304)
	Number of cases with available data (% of total cases)	Reported cases (% of available cases)	Number of cases with available data (% of total cases)	Reported cases (% of available cases)	Reported cases (% of available cases)	Reported cases (% of available cases)
<b>Complete triad<sup>a</sup></b>	311 (93.6)	111 (35.7)	247 (81)	31 (13)	187 (60)	252 (85)
<b>CNS involvement</b>	311 (93.6)	213 (68.5)	247 (81)	165 (67)	285 (91)	274 (91)
<b>Ocular involvement</b>	311 (93.6)	190 (61.1)	248 (82)	99 (40)	262 (84)	293 (97)
<b>Neuro-otological involvement</b>	311 (93.6)	161 (51.8)	248 (82)	91 (37)	285 (67)	288 (96)
<b>Headache</b>	311 (93.6)	165 (53%)	182 (60)	141 (78)	Not available	171 (87)

<sup>a</sup> Concomitant clinical involvement of CNS (excluding asymptomatic MRI abnormalities), eye (including asymptomatic branch retinal artery occlusion), and neuro-otological.

previous review, prior infections were reported in 6.2% of available cases. Taken together, these data do not support a clear connection between infectious trigger and SuS manifestation. Because the diagnosis of patients with SuS may be long after the start of the disease, it is possible that infectious causes were missed. Further research is needed to determine the association between the 2.

### Clinical Course at Onset and During Follow-Up

Clinical presentation at disease onset was available in 311 cases (93.6%) (Table 2). Only 111 patients (35.7%) were reported to have the complete clinical triad at presentation. CNS symptoms were the most common presenting feature (68.5%). Most patients reported headache at presentation, a nonspecific finding which was previously reported and described as migraine-like headache (Dörr et al, 2013). The diagnostic criteria of the European Susac Consortium acknowledge headache as a possible brain manifestation if it is new, migrainous, or oppressive and precedes the other symptoms by not more than 6 months.<sup>11</sup> Migraine-like headache as a symptom of SuS could have different presentations in relation to the manifestation of SuS: exacerbation and chronification of headache just before the onset of the first symptoms of SuS, the manifestation of migraine-like headache during the first SuS episode, and an increasing frequency of headache during the course of the disease.<sup>30</sup>

Ocular and neuro-otological involvement were reported in 190 (61.1%) and 161 (51.8%) of cases, respectively. These numbers represent a numerical increase compared with our previous data,<sup>6</sup> which is probably because of increased awareness and the use of ancillary tests. It is now becoming obvious that the diagnosis of SuS should not be solely on the basis of the complete triad, and a targeted search for sub-clinical involvement using diagnostic imaging, fluorescein angiography (FA), and audiometry is needed.

During disease with a mean follow-up of 36 months, the complete triad was documented in 60% of cases with available data.

The remaining 40% of cases were interpreted as incomplete SuS, had an incomplete diagnostic workup, or were not sufficiently described. Neurologic (91%), ophthalmologic (84%), and neuro-otological (67%) manifestations occurred at similar proportions in most cases during disease. Neuro-otological involvement remains the least reported manifestation (67%). CNS manifestations are described in Table 3. The most common CNS symptoms were neuropsychiatric and included cognitive impairment, confusion, and emotional and behavioral disturbances as previously reported.<sup>6</sup> In the 2 cohorts together, 49% of patients with SuS suffered from confusion and 49% from cognitive impairment. These features are difficult to define and are not uniform from one case report to the other. Because they are nonspecific, caution should be taken in patients in which the presentation is mainly neuropsychiatric, and an extensive objective evaluation including the search for asymptomatic eye involvement can be crucial for the diagnosis. Only 6% of patients with SuS had ocular symptoms, which emphasized that ocular involvement can often be subclinical. Tinnitus was reported in 32% in total, and vertigo were reported in 22% in our current cohort. Vertigo was not described in our previous review, and it is now emerging as an important symptom. While a proportion of these patients may have vertigo because of brainstem or cerebellar involvement, in others, it may reflect peripheral vestibular pathology. Detailed study of vestibular involvement in SuS is lacking although the diagnostic criteria require an abnormal testing. In a recent publication on the neuro-otology of SuS, caloric testing and vestibular-evoked myogenic potentials (VEMP) were pathologic in 3 patients with SuS, demonstrating horizontal semicircular canal dysfunction in one and utricular dysfunction and saccular deficits in others.<sup>31</sup>

### Diagnostic Procedures

#### Cerebrospinal Fluid Analysis

CSF analysis was available in 174 patients with SuS (52.4%) (Table 4). The most common CSF finding was an elevation of

**Table 3** Clinical Manifestations of Susac Syndrome

Manifestation	2023 Review Reported cases Number of cases (% of available cases) N = 237	2013 Review Reported cases Number of cases (% of available cases) N = 304	Total Reported cases Number of cases (% of available cases) N = 541
<b>CNS</b>			
Confusion	145 (61)	119 (39)	265 (49)
Cognitive impairment	122 (51)	146 (48)	268 (49)
Ataxia	91 (38)	77 (25)	168 (31)
Emotional/behavioral disturbances	72 (30)	48 (16)	120 (22)
Pyramidal signs	61 (26)	63 (21)	124 (23)
Reduction of vigilance	56 (24)	26 (9)	82 (15)
Sensory disturbance	50 (21)	73 (24)	123 (23)
Aphasia/dysarthria	40 (17)	40 (13)	80 (15)
Psychosis	10 (4)	29 (10)	39 (7)
Oculomotor dysfunction	5 (2)	29 (10)	34 (6)
<b>Neuro-otological</b>			
Tinnitus	88 (37)	88 (29)	176 (32)
Vertigo	53 (22)		

total protein in 150 patients (86.2%) similar to the 2013 article (84%), with a mean total protein level of  $1.8 \pm 3.2$  (g/L). Pleocytosis ( $\geq 5$  cells/ $\mu$ L) was reported in 68 patients (39.1%), with a mean CSF cell count of  $11.9 \pm 16$  (cells/ $\mu$ L). Oligoclonal bands (OCBs) were reported in only 9 patients (11.7%) and IgG index elevation in 4 (8.9%) more patients. Together these numbers are similar to our previous review; therefore, the presence of OCB by itself does not exclude the diagnosis of Susac syndrome.

### MRI Findings

Cranial MRI was available in 313 patients with SuS (96.9%). Figure 2 presents specific lesion locations and MRI sequences performed in the current cohort compared with the 2013 data. Most reported cases ( $n = 265$  (84.7%)) had the typical involvement of the corpus callosum. Other often involved brain regions included the periventricular area in 98 (31.3%), the subcortex in 86 (27.5%), and the internal capsule in 26 patients with SuS (8.3%). Lesions in the basal ganglia and thalamus were reported in 46 (14.7%) and 19 (6.1%) of cases, respectively. These numbers are lower compared with the 2013 article what can be due to lack of information regarding specific areas in our current review. Infratentorial brain lesions were less frequently reported. Cerebellar manifestation was the most common infratentorial finding in 58 (17.6%). Lesions in the middle cerebellar peduncle ( $n = 20$  (6.4%)) and in the brainstem ( $n = 28$  (8.9%)) were rather rare. Diffusion-restricted lesions were more common than gadolinium-enhancing lesions ( $n = 87$  (27.8%) vs  $n = 59$  (18.8%)). Data on diffusion-weighted MRI were not available in the 2013

article, and it is now emerging as an important MRI sequence in the diagnosis and follow-up of patients with SuS. Cauda equina involvement was reported in 2 patients with SuS.<sup>32,33</sup>

Leptomeningeal enhancement (LME) is considered a supportive diagnostic finding by the current diagnostic criteria.<sup>11</sup> LME was observed in 45 patients with SuS (14.4%). In a retrospective study of 25 definite patients with SuS, LME was always observed and easily visible on postcontrast FLAIR images and was highly indicative of SuS.<sup>34</sup> LME indicates active disease and is proportional to disease severity. It preferentially and uniquely involves the posterior fossa.<sup>35</sup> It should be noted that LME can be detected in other inflammatory diseases such as myelin oligodendrocyte glycoprotein antibody-associated disease (MOGAD).<sup>36</sup> Unfortunately, postcontrast FLAIR sequences are usually off-routine, and therefore, data on LME are sparse. Vessel wall imaging is an emerging imaging modality for demonstrating vasculitis. Black-blood protocols suppress blood flow signal, which can aid demonstration of vessel wall inflammation. Specific patterns of perivascular enhancement supporting small vessel vasculopathy have been recognized in SuS.<sup>37</sup> However, this particular enhancement pattern was reported only in 2 of our reviewed cases.

### Ocular Diagnostic Procedures

FA was available in 250 cases (75.3%) and revealed BRAO in 219 patients with SuS (87.6%). In our previous review, BRAO was demonstrated in 99% of patients with SuS. In the new cohort, BRAO was bilateral in 56 (34.4%), unilateral in 32 (12.8%), and without reported lateralization in 84 patients



**Table 4** Diagnostic Tests of Patients With Susac Syndrome

Feature	2023 review (N = 332)		2013 review (N = 304)	
	Number of cases with data	Description (% of cases)	Number of cases with data	Description (% of cases)
<b>CSF analysis</b>				
<b>Pleocytosis</b>	174	68 (39.1)	209	93 (45)
<b>Elevated total protein</b>	174	150 (86.2)	207	173 (84)
<b>Positive OCB</b>	77	9 (11.7)	129	5 (4)
<b>IgG index elevation</b>	45	4 (8.9)	86	13 (15)
<b>Branch retinal artery occlusions on retinal fluorescein angiography</b>				
<b>Unilateral</b>		32 (12.8)		
<b>Bilateral</b>		86 (34.4)		
<b>Unknown</b>		84 (33.6)		
<b>Arterial wall hyperfluorescence on retinal fluorescein angiography</b>				
<b>Unilateral</b>	122	88 (72.1)	83	80 (96)
<b>Bilateral</b>		10 (8.2)		
<b>Unknown</b>		16 (13.1)		
<b>Unknown</b>		59 (48.4)		
<b>Gass plaques on funduscopy</b>	187	21 (11.2)		
<b>Retinal ischemia on OCT</b>	68	46 (67.6)		
<b>Retinal ischemia on OCT-A</b>	49	22 (44.9)		
<b>Sensory-neuronal hearing loss</b>				
<b>Unilateral</b>	259	45 (17.4)	213	57 (27)
<b>Bilateral</b>		90 (34.7)		147 (69)
<b>Unknown</b>		100 (38.6)		
<b>Sensory-neuronal hearing loss type</b>				
<b>Low frequency</b>	114	85 (74.6)		
<b>Medium-high frequency</b>		8 (7)		
<b>Pan frequency</b>		21 (18.4)		
<b>Functional testing</b>				
<b>Abnormal auditory-evoked potentials</b>	59	8 (13.6)		
<b>Abnormal vestibular tests</b>	53	10 (18.9)		

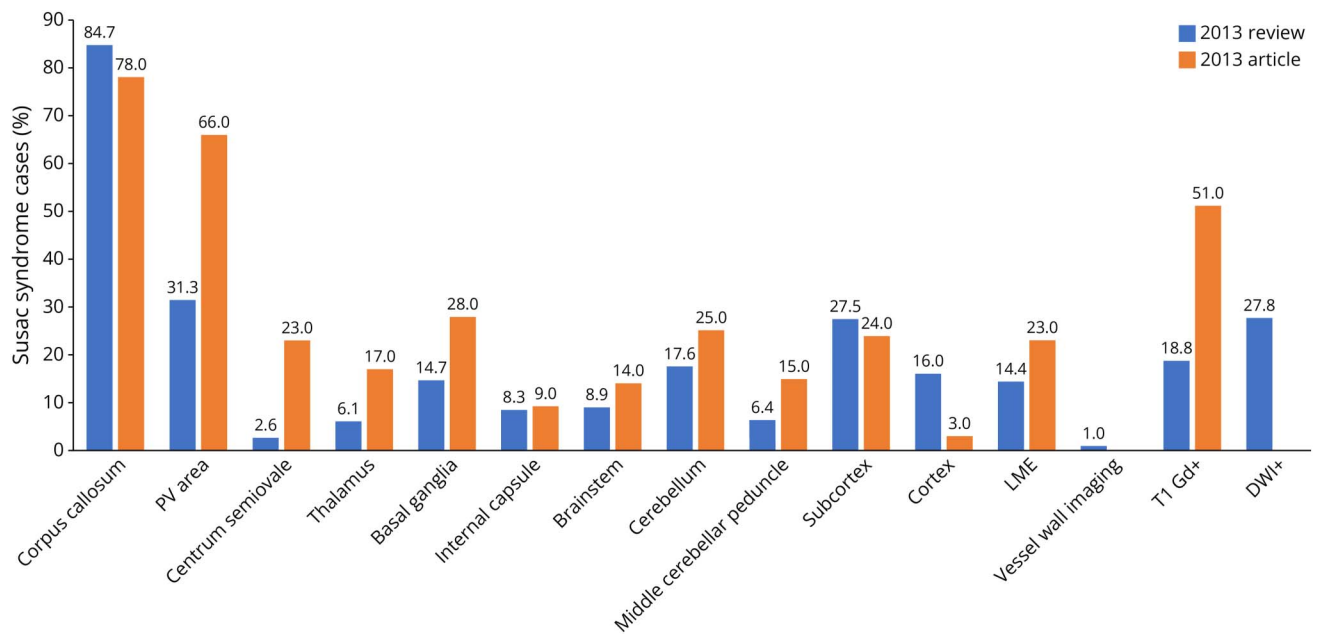
Abbreviations: OCT, optical coherence tomography; OCT-A, optical coherence tomography angiography.

(33.6%). BRAO was not found only in 17 patients with SuS (5%) (Table 4). Arterial wall hyperfluorescence (AWH) was reported in 88 (72.1%), and Gass plaques on funduscopy were reported in 21 patients with SuS (11.2%). Optical coherence tomography (OCT) was performed in 68 patients with SuS (21.7%) and demonstrated ischemia in 46 (67.6%). OCT data were not available in our previous review.

OCT-angiography (OCT-A) assesses retinal microcirculation and perfusion with possibly greater sensitivity than FA.<sup>38</sup> OCT-A in SuS characteristically demonstrates low-flow areas

that represent decreased retinal capillary density and perfusion due to occluded arterioles. It can also detect reperfusion in these areas, supporting its use during follow-up. Because it is a relatively new method, data were reported in only 49 patients with SuS (15.6%) and demonstrated ischemia in 22 patients (44.9%). In a recently published article evaluating the utility of OCT-A in 9 patients with chronic SuS, it was shown that skeleton and inner ring vessel density were significantly lower in patients with SuS, while eccentricity and axis ratio were significantly higher. SuS eyes (affected and unaffected) had poorer outcomes of the remaining vascular parameters

**Figure 2** Location of Brain Lesions in Patients With Susac Syndrome



Graph shows percentage of Susac syndrome cases with lesions at each brain location in 2023 review compared with 2013, as observed on different MRI sequences. Percentages are based on data from 313 (96.9% of all cases) and 204 (64% of all cases) patients from whom imaging data was available in the 2013 and 2023 cohorts, respectively. Corp. call. = corpus callosum; DWI = diffusion-weighted imaging; Gd = gadolinium; Int. caps. = internal capsule; LME = leptomeningeal enhancement; Mid. cereb. = ped middle cerebellar peduncle; PV = periventricular.

compared with controls. OCT-A identified chronic microvascular changes in the eyes of patients with chronic SuS. Although further research is needed, this noninvasive imaging modality seems to have the potential to serve as a valuable additive diagnostic tool with high sensitivity in diagnosing reduced perfusion for the acute phase and follow-up in patients with SuS.<sup>39</sup>

Ultra-widefield (UWF) imaging allows panoramic inspection for ischemic changes in the outermost parts of the retina which are typically involved in SuS. It thus has the potential to increase diagnostic certainty and follow-up accuracy in SuS. UWF can be applied in various modalities, including FA and OCTA.<sup>40</sup>

Disease activity-FA (DA-FA) score, as a comprehensive disease activity parameter in SuS, has a potential to facilitate optimal communication between subspecialties and thereby treatment success.<sup>41</sup> In 7 patients with SuS, with a median age of 36 years, serial UWF-FA studies were performed, with adjunctive widefield OCT-A in 5 patients. In all 7 patients, BRAO and AWH were present in UWF-FA and calculated as a quantitative score of disease activity in fluorescein angiography during follow-up visits. Treatment response was evaluated in follow-up imaging as partial reperfusion of retinal vessels, resolution of AWH, and consequently in reduction of DA-FA score. Overall, quantitative assessment of disease activity in SuS in form of DA-FA score allows for a comprehensive disease activity figure. Interdisciplinary comprehensibility of findings is of uttermost importance in the management of patients with SuS: Several

clinics and physicians of various subspecialties are required to communicate patient status, treatment plans, and their response or nonresponse to a proposed treatment.

### Vestibulocochlear Diagnostic Procedures

Audiometry was reported in 259 patients with SuS (82.7%), and SNHL was demonstrated at 235 (90%), similar to our previously review (Table 4). Lateralization was reported in 135 patients and was bilateral in 34.7%. In 85 (74.6%), hearing loss involved low-middle frequencies, as previously reported, and in 8 (7%) patients medium-high frequencies. It should be noted that high-frequency SNHL is rare but does not exclude SuS. Pathologic auditory-evoked potentials were demonstrated in 8/59 patients with SuS (13.6%). Vestibular functional testing was performed in 53 patients with SuS (16%) with pathologic findings in 10 (18.9%). According to one article,<sup>31</sup> 1 of 4 definite patients with SuS had a pathologic video head impulse test (vHIT), and 2 patients had abnormal VEMP that resolved. Owing to the currently sparse use of these methods, we cannot evaluate their utility in the context of SuS. However, it is important to consider these tests when evaluating a patient with suspected SuS that cannot perform audiometry because of concurrent encephalopathy or other reasons.

### Other Procedures

Antiendothelial cell antibodies (AECA), also hypothesized to be of pathophysiologic relevance in SuS, were detected in 1 patient<sup>22</sup> from 3 patients with SuS who were tested.<sup>42,43</sup> In the 2013 article, AECA were found in 11 patients. Based on these

findings, broad screening for autoantibodies in patients with suspected SuS is not a common procedure. These findings are in line with recent work demonstrating that CD8<sup>+</sup> T-cell-mediated endotheliopathy seem to be a key player in the disease pathophysiology of SuS.<sup>44</sup>

Brain biopsy was reported in 17 patients with SuS (5%). It was normal in 2 reported cases<sup>27,33</sup> and inconclusive in 2 more cases.<sup>41</sup> A few pathologic findings demonstrated immune endotheliopathy,<sup>25,45,46</sup> perivascular demyelination, and a diffuse pial infiltrate dominated by CD8 T lymphocytes and macrophages with microinfarctions in the territory of the small vessels.<sup>47</sup> In an electron microscopic study of 5 cases, the key findings were basement membrane thickening and collagen deposition in the perivascular space involving small vessels and leading to thickening of vessel walls, narrowing, and vascular occlusion.<sup>4</sup> These findings indicate that SuS is a microvascular disease. Mononuclear cells were present in the perivascular space, underlining the inflammatory nature of the pathology.<sup>4</sup> All together, we can conclude that brain biopsy is unnecessary in establishing SuS diagnosis and should be limited to special cases in which the diagnosis is not clear.

Brain angiography was reported in only 3 patients with SuS. In 1 patient, it revealed mild tortuosity of the pericallosal artery<sup>25</sup> and in another patient abnormal small irregularities in the distal anterior and middle cerebral artery branch<sup>48</sup> and was normal in the third patient.<sup>49</sup> In our previous report, brain angiography was performed in a substantial number of patients, but most studies reported normal findings. Because the vessels affected in Susac syndrome are too small to be depicted on angiography, this procedure should be reserved for special cases—for example, when cerebral vasculitis is suspected.

### Classification According to the 2016 Criteria

According to the criteria proposed by Kleffner et al. in 2016, patients with definite SuS must have brain and vestibulocochlear involvement with both clinical manifestations and findings in objective testing and ocular involvement which may be present in objective testing alone. We classified the current cohort according to the 2016 criteria. A total of 169 patients (50.9%) fulfilled the definition of definite SuS according to these criteria. 163 (49.1%) patients did not meet the “definite” criteria and were defined probable SuS.

We analyzed which specific criterion was missing to meet definite SuS. This analysis was performed only in case studies in which specific data for patient were provided (n = 67). The most often missing criterion was vestibulocochlear involvement in 26 patients (39%), from which, 9 (23%) did not have any vestibulocochlear involvement, 4 (20%) did not have clinical SNHL, and 13 (33%) did not have a test demonstrating SNHL. Only 2 patients (3%) had no retinal involvement, and in 6 patients (9%), a supporting ophthalmologic examination was not available. Three patients with SuS (4%) had MRI supporting CNS involvement with no clinical presentation (including headache),

and in 1 patient, the lack of corpus callosum involvement on MRI was the sole missing criterion.

These results may imply that these criteria may not be sensitive enough for the diagnosis of SuS. We think, however, that data are not yet robust enough to draw any specific recommendations for now, but future collaborative work with other centers will facilitate a more comprehensive database.

### Limitations

Data regarding SuS have greatly expanded during the last decade. Therefore, most of the articles that were published in recent years are case series. In addition, many of these publications focus on new diagnostic techniques as part of SuS evaluation, which often resulted in partial description of the manifestation and do not provide the comprehensive data that were necessary for this review. Whenever the authors declared a previous publication of a particular patient, we removed the respective data to avoid duplication. However, we cannot completely rule out the possibility of some duplication. “Normal” SuS with no unusual features and unspectacular course are less likely to be published and therefore underrepresented. Treatment response was beyond the scope of our review and is discussed in a recently published review.<sup>50</sup>

### Conclusions

In this systematic review, we present updated epidemiology data of SuS, classified by our recently proposed criteria, and summarized newly used diagnostic methods for evaluation of brain, ocular, and vestibulocochlear involvement. Our data show similar demographic and clinical manifestations compared with our previous review which strengthen our current results and the clinical manifestation of SuS. Moreover, we describe current and updated ancillary tests. Our results support early and extensive ophthalmologic evaluation including FA and OCT in patients presenting with neurocognitive symptoms and suggestive MRI findings. Specific MRI sequences such as DWI and postcontrast FLAIR should be added to increased sensitivity when SuS is suspected. The fact that only half of the patients were defined as definite SuS and the progress in ancillary tests suggest an update of the current SuS diagnostic criteria.

### Study Funding

The authors report no targeted funding.

### Disclosure

The authors report no relevant disclosures. Go to Neurology.org/NN for full disclosures.

### Publication History

Received by *Neurology: Neuroimmunology & Neuroinflammation* October 10, 2023. Accepted in final form January 2, 2024. Submitted and externally peer reviewed. The handling editor was Editor Josep O. Dalmau, MD, PhD, FAAN.



## Appendix Authors

Name	Location	Contribution
<b>Adi Wilf-Yarkoni, MD, BSc</b>	Department of Neurology, Rabin Medical Center, Petah Tikva; Department of Neurology and Neurosurgery, Sackler Faculty of Medicine, Tel Aviv University, Israel	Drafting/revision of the manuscript for content, including medical writing for content; major role in the acquisition of data; study concept or design; analysis or interpretation of data
<b>Ofir Zmira, MD</b>	Department of Neurology, Hillel Yaffe Medical Center, Hadera; Department of Neurology, Ruth and Bruce Rappaport Faculty of Medicine, Technion Institute of Technology, Haifa, Israel	Drafting/revision of the manuscript for content, including medical writing for content; major role in the acquisition of data; study concept or design; analysis or interpretation of data
<b>Assaf Tolkovsky, MD</b>	Department of Neurology, Rabin Medical Center, Petah Tikva; Department of Neurology and Neurosurgery, Sackler Faculty of Medicine, Tel Aviv University, Israel	Major role in the acquisition of data; analysis or interpretation of data
<b>Barak Pflantzer, MD</b>	Department of Neurology and Neurosurgery, Sackler Faculty of Medicine, Tel Aviv University; Department of Neurology, Sheba Medical Center, Ramat Gan, Israel	Major role in the acquisition of data
<b>Shany G. Gofrit, MD</b>	Department of Neurology and Neurosurgery, Sackler Faculty of Medicine, Tel Aviv University; Department of Neurology, Sheba Medical Center, Ramat Gan, Israel	Major role in the acquisition of data; analysis or interpretation of data
<b>Ilka Kleffner, MD</b>	Department of Neurology, University Hospital Knappschaftskrankenhaus Bochum, Ruhr University Bochum, Germany	Drafting/revision of the manuscript for content, including medical writing for content
<b>Friedemann Paul, MD</b>	Experimental and Clinical Research Center, Max Delbrueck Center for Molecular Medicine and Charité Universitaetsmedizin Berlin, Berlin, Germany	Drafting/revision of the manuscript for content, including medical writing for content; study concept or design
<b>Jan Dörr, MD</b>	Experimental and Clinical Research Center, Max Delbrueck Center for Molecular Medicine and Charité Universitaetsmedizin Berlin; Multiple Sclerosis Center, Neurology Department, Oberhavel Kliniken, Hennigsdorf, Germany	Drafting/revision of the manuscript for content, including medical writing for content; study concept or design; analysis or interpretation of data

## References

- Susac JO, Hardman JM, Selhorst JB. Microangiopathy of the brain and retina. *Neurology*. 1979;29(3):313-316. doi:10.1212/wnl.29.3.313
- Jarius S, Kleffner I, Dörr JM, et al. Clinical, paraclinical and serological findings in Susac syndrome: an international multicenter study. *J Neuroinflammation*. 2014;11:46. doi:10.1186/1742-2094-11-46
- Magro CM, Poe JC, Lubow M, Susac JO. Susac syndrome: an organ-specific autoimmune endotheliopathy syndrome associated with anti-endothelial cell antibodies. *Am J Clin Pathol*. 2011;136(6):903-912. doi:10.1309/AJCPER17LC4VNFYK
- Agamanolis DP, Prayson RA, Asdaghi N, Gultekin SH, Bigley K, Rennebohm RM. Brain microvascular pathology in Susac syndrome: an electron microscopic study of five cases. *Ultrastruct Pathol*. 2019;43(6):229-236. doi:10.1080/01913123.2019.1692117
- Agamanolis DP, Klönc C, Bigley K, Rennebohm RM. Neuropathological findings in susac syndrome: an autopsy report. *J Neuropathol Exp Neurol*. 2019;78(6):515-519. doi:10.1093/jnen/nlz031
- Dörr J, Krautwald S, Wildemann B, et al. Characteristics of Susac syndrome: a review of all reported cases. *Nat Rev Neurol*. 2013;9(6):307-316. doi:10.1038/nrneuro.2013.82
- O'Halloran HS, Pearson PA, Lee WB, Susac JO, Berger JR. Microangiopathy of the brain, retina, and cochlea (Susac syndrome). A report of five cases and a review of the literature. *Ophthalmology*. 1998;105(6):1038-1044. doi:10.1016/S0161-6420(98)96005-5
- Marrodan M, Fiol MP, Correale J. Susac syndrome: challenges in the diagnosis and treatment. *Brain*. 2022;145(3):858-871. doi:10.1093/brain/awab476
- Rennebohm RM, Asdaghi N, Srivastava S, Gertner E. Guidelines for treatment of Susac syndrome—an update. *Int J Stroke*. 2020;15(5):484-494. doi:10.1177/1747493017751737
- Vishnevskia-Dai V, Chapman J, Sheinfeld R, et al. Susac syndrome: clinical characteristics, clinical classification, and long-term prognosis. *Medicine (Baltimore)*. 2016;95(43):e5223. doi:10.1097/MD.0000000000005223
- Kleffner I, Dörr J, Ringelstein M, et al. Diagnostic criteria for Susac syndrome. *J Neurol Neurosurg Psychiatry*. 2016;87(12):1287-1295. doi:10.1136/jnnp-2016-314295
- Page MJ, Moher D, Bossuyt PM, et al. PRISMA 2020 explanation and elaboration: updated guidance and exemplars for reporting systematic reviews. *BMJ*. 2021;372:n160. doi:10.1136/bmj.n160
- Aubart-Cohen F, Klein I, Alexandra JF, et al. Long-term outcome in Susac syndrome. *Medicine (Baltimore)*. 2007;86(2):93-102. doi:10.1097/MD.0b013e3180404c99
- Rennebohm RM, Egan RA, Susac JO. Treatment of Susac's syndrome. *Curr Treat Options Neurol*. 2008;10(1):67-74. doi:10.1007/s11940-008-0008-y
- Chiossi G, Neri I, Cavazzuti M, Basso G, Facchinetti F. Hyperemesis gravidarum complicated by Wernicke encephalopathy: background, case report, and review of the literature. *Obstet Gynecol Surv*. 2006;61(4):255-268. doi:10.1097/01.ogx.0000206336.08794.65
- Singh S, Mohakud S, Naik S, Jena SK, Sethi P, Nayak P. Predictors of posterior reversible encephalopathy syndrome in women with hypertension in pregnancy: a prospective observational study. *Pregnancy Hypertens*. 2021;23:191-195. doi:10.1016/j.preghy.2020.12.006
- Tang K, Zhou J, Lan Y, Zhang H, Jin H. Pregnancy in adult-onset dermatomyositis/polymyositis: a systematic review. *Am J Reprod Immunol*. 2022;88(5):e13603. doi:10.1111/aji.13603
- Willekens B, Kleffner I. Susac syndrome and pregnancy: a review of published cases and considerations for patient management. *Ther Adv Neurol Disord*. 2021;14:1756286420981352. doi:10.1177/1756286420981352
- Ferretti F, Gerevini S, Colombo B, et al. Susac's syndrome as HIV-associated immune reconstitution inflammatory syndrome. *AIDS Res Ther*. 2013;10(1):22. doi:10.1186/1742-6405-10-22
- Longbrake EE, Ances BM, Viets RB, Clifford DB. Susac syndrome in a patient with human immunodeficiency virus infection. *J Neurovirol*. 2013;19(3):270-273. doi:10.1007/s13365-013-0164-z
- Raymaekers V, D'Hulst S, Herijgers D, et al. Susac syndrome complicating a SARS-CoV-2 infection. *J Neurovirol*. 2021;27(6):954-959. doi:10.1007/s13365-021-01022-7
- Venditti L, Rousseau A, Ancelet C, Papo T, Denier C. Susac syndrome following COVID-19 infection. *Acta Neurol Belg*. 2021;121(3):807-809. doi:10.1007/s13760-020-01554-5
- Schottlaender LV, Correale J, Ameriso SF, et al. White matter relapsing remitting disease: "Susac's syndrome"—An underdiagnosed entity. *Mult Scler Relat Disord*. 2013;2(4):349-354. doi:10.1016/j.msard.2013.02.007
- Kleffner I, Dörr J, Duning T, Young P, Ringelstein EB, Schilling M. Susac syndrome treated with subcutaneous immunoglobulin. *Eur Neurol*. 2014;71(1-2):89-92. doi:10.1159/000354181
- Gil-Gouveia R, Marto N, Vilela P, Catarino A. Anecdotal response to amphotericin in a patient with probable susac syndrome: implications in the pathogenesis. *Acta Med Port*. 2019;32(11):727-730. doi:10.20344/amp.10541
- Mora López D, Trisanchó Garzon A, Guzmán Llorente M, Jiménez Conde C, Montero Urbina A, Oliva Fernández P. Susac's syndrome. A case of autoimmune encephalitis. *Med Intensiva (Engl Ed)*. 2019;43(3):182-184. doi:10.1016/j.medint.2017.07.009
- Wilf-Yarkoni A, Elkayam O, Aizenstein O, et al. Increased incidence of Susac syndrome: a case series study. *BMC Neurol*. 2020;20(1):332. doi:10.1186/s12883-020-01892-0
- Rivadeneira-Sotelo C, Meza Vega M, Segura-Chávez D, Castro-Suarez S. Susac syndrome: the first case report in Peru. *Medwave*. 2017;17(7):e7033. doi:10.5867/medwave.2017.07.7033
- Marrodan M, Correale J, Alessandro L, et al. Susac Syndrome: a differential diagnosis of white matter lesions. *Mult Scler Relat Disord*. 2017;15:42-46. doi:10.1016/j.msard.2017.04.007
- Obelieniene D, Macaityte R, Balnyte R, Pestininkaitė R, Gleizniene R, Balciuniene J. Characteristics of headache in relation to the manifestation of Susac syndrome. *Medicina (Kaunas)*. 2017;53(6):420-425. doi:10.1016/j.medici.2018.01.003
- Hardy TA, Taylor RL, Qiu J, et al. The neuro-otology of Susac syndrome. *J Neurol*. 2020;267(12):3711-3722. doi:10.1007/s00415-020-10086-0
- Allmendinger AM, Mallery RM, Magro CM, et al. Cauda equina involvement in Susac's syndrome. *J Neurol Sci*. 2014;337(1-2):91-96. doi:10.1016/j.jns.2013.11.023
- Allmendinger AM, Viswanadhan N, Klufas RA, Hsu L. Diffuse cauda equina enhancement in a middle aged male with Susac syndrome and symptomatic cauda equina syndrome. *J Neurol Sci*. 2013;333(1-2):25-28. doi:10.1016/j.jns.2013.06.017
- Bellanger G, Biotti D, Adam G, et al. Leptomeningeal enhancement on post-contrast FLAIR images for early diagnosis of Susac syndrome. *Mult Scler*. 2022;28(2):189-197. doi:10.1177/13524585211012349

35. Coulette S, Lecler A, Saragoussi E, et al. Diagnosis and prediction of relapses in Susac syndrome: a new use for MR postcontrast FLAIR leptomeningeal enhancement. *AJNR Am J Neuroradiol*. 2019;40(7):1184-1190. doi:10.3174/ajnr.A6103
36. Elsbernd P, Cacciaguerra L, Krecke KN, et al. Cerebral enhancement in MOG antibody-associated disease. *J Neurol Neurosurg Psychiatry*. 2023;95(1):14-18. doi:10.1136/jnnp-2023-331137
37. Yahyavi-Firouz-Abadi N, Kiczek M, Zeiler SR, Wasserman BA. Imaging features of Susac syndrome on high-resolution intracranial vessel wall MRI. *Neurol Neuroimmunol Neuroinflamm*. 2021;8(4):e994. doi:10.1212/NXL.0000000000000994
38. Bagaglia SA, Passani F, Oliverio GW, et al. Multimodal imaging in Susac syndrome: a case report and literature review. *Int J Environ Res Public Health*. 2021;18(7):3435. doi:10.3390/ijerph18073435
39. Wirth MA, Khan HM, Chan J, et al. Investigating microangiopathy using swept-source optical coherence tomography angiography in patients with Susac syndrome. *Retina*. 2021;41(10):2172-2178. doi:10.1097/IAE.0000000000003170
40. Salvano P, Moe MC, Utheim TP, Bragadottir R, Kerty E. Ultra-wide-field fundus imaging in the diagnosis and follow-up of Susac syndrome. *Retin Cases Brief Rep*. 2018;12(3):234-239. doi:10.1097/ICB.0000000000000470
41. Hamann T, Wiest M, Innes W, Zweifel S. A novel quantitative assessment method of disease activity in Susac's syndrome based on ultra-wide field imaging. *Curr Eye Res*. 2022;47(2):262-268. doi:10.1080/02713683.2021.1967402
42. Pérez-Lombardo M, Alberdi-Páramo I, Ramos-Barragán B, Gimeno-Álvarez D. Confusion, dissociation and bizarre behaviour as the onset of an early Susac syndrome. *BMJ Case Rep*. 2019;12(8):e229422. doi:10.1136/bcr-2019-229422
43. Alungulesc AL, Garcia Soldevilla MA, Barragan Martinez D, Gordo Manas R. Sex hormones secondary players in Susac's syndrome. *Mult Scler Relat Disord*. 2020;44:102373. doi:10.1016/j.msard.2020.102373
44. Gross CC, Meyer C, Bhatia U, et al. CD8(+) T cell-mediated endotheliopathy is a targetable mechanism of neuro-inflammation in Susac syndrome. *Nat Commun*. 2019;10(1):5779. doi:10.1038/s41467-019-13593-5
45. Antulov R, Holjar Eric I, Perkovic O, Miletic D, Antoncic I. Susac's syndrome during pregnancy - the first Croatian case. *J Neurol Sci*. 2014;341(1-2):162-164. doi:10.1016/j.jns.2014.04.010
46. Hardy TA, O'Brien B, Gerbis N, et al. Brain histopathology in three cases of Susac's syndrome: implications for lesion pathogenesis and treatment. *J Neurol Neurosurg Psychiatry*. 2015;86(5):582-584. doi:10.1136/jnnp-2014-308240
47. Fernando SL, Boyle T, Smith A, Parratt JDE. The successful use of infliximab in a relapsing case of Susac's syndrome. *Case Rep Neurol Med*. 2020;2020:9317232. doi:10.1155/2020/9317232
48. Yang YS, Zhang L, Asdaghi N, Henry CR, Davis JL. Acute macular neuroretinopathy in Susac syndrome: a new association. *Retin Cases Brief Rep*. 2020;14(4):310-314. doi:10.1097/ICB.0000000000000738
49. Demuth S, Bogdan T, Kremer L, et al. Good therapeutic response to infliximab in a case of Susac syndrome refractory to immunotherapies including tocilizumab. *J Neurol*. 2022;269(6):3347-3350. doi:10.1007/s00415-021-10922-x
50. Stinissen R, Tukanov E, Wyckmans M, Kerstens J, Willekens B. Clinical characteristics and treatment approaches in patients with Susac syndrome: a scoping review of cases. *J Neurol*. 2023;270(12):5719-5730. doi:10.1007/s00415-023-11936-3