

# The OSCAR-MP Consensus Criteria for Quality Assessment of Retinal Optical Coherence Tomography Angiography

Rebecca Wicklein, MD, Charmaine Yam, MD, Christina Noll, MD, Lilian Aly, MD, Nicolas Banze, Eva Feodora Romahn, Elisabeth Wolf, Bernhard Hemmer, MD, Frederike C. Oertel, MD, PhD, Hanna Zimmermann, PhD, Philipp Albrecht, MD, Marius Ringelstein, MD, Carmen Baumann, MD, Nikolaus Feucht, MD, Josef Penkava, MD, Joachim Havla, MD, Jonathan A. Gernert, MD, Christian Mardin, MD, FEBO, Eleni S. Vasileiou, MD, Anneke Van Der Walt, MBChB, PhD, Omar Al-Louzi, MD, Sergio Cabello, Angela Vidal-Jordana, MD, PhD, Julia Krämer, MD, Heinz Wiendl, MD, Jana Lizrova Preiningerova, MD, PhD, Olga Ciccarelli, MD, PhD, Elena Garcia-Martin, MD, PhD, Veronika Kana, MD, Peter A. Calabresi, MD, Friedemann Paul, MD, Shiv Saidha, MBBCh, MD, Axel Petzold, MD, PhD, Ahmed T. Toosy, MD, PhD, FRCP, Benjamin Knier, MD, on behalf of IMSVISUAL Consortium

## Correspondence

Dr. Knier  
benjamin.knier@tum.de

*Neurol Neuroimmunol Neuroinflamm* 2023;10:e200169. doi:10.1212/NXI.000000000200169

## Abstract

### Background and Objectives

Optical coherence tomography angiography (OCTA) is a noninvasive high-resolution imaging technique for assessing the retinal vasculature and is increasingly used in various ophthalmologic, neuro-ophthalmologic, and neurologic diseases. To date, there are no validated consensus criteria for quality control (QC) of OCTA. Our study aimed to develop criteria for OCTA quality assessment.

### Methods

To establish criteria through (1) extensive literature review on OCTA artifacts and image quality to generate standardized and easy-to-apply OCTA QC criteria, (2) application of OCTA QC criteria to evaluate interrater agreement, (3) identification of reasons for interrater disagreement, revision of OCTA QC criteria, development of OCTA QC scoring guide and training set, and (4) validation of QC criteria in an international, interdisciplinary multicenter study.

### Results

We identified 7 major aspects that affect OCTA quality: (O) obvious problems, (S) signal strength, (C) centration, (A) algorithm failure, (R) retinal pathology, (M) motion artifacts, and (P) projection artifacts. Seven independent raters applied the OSCAR-MP criteria to a set of 40 OCTA scans from people with MS, Sjogren syndrome, and uveitis and healthy individuals. The

From the Department of Neurology (R.W., C.N., L.A., N.B., E.F.R., E.W., B.H., B.K.), Klinikum rechts der Isar, TUM School of Medicine, Technical University of Munich, Germany; Department of Neuroinflammation (C.Y., O.C., A.P., A.T.T.), Queen Square MS Centre, Faculty of Brain Sciences, UCL Queen Square Institute of Neurology, University College London; Neurosciences Institute (C.Y.), Cleveland Clinic London, United Kingdom; Munich Cluster for Systems Neurology (SyNergy) (B.H.), Munich, Germany; Experimental and Clinical Research Center (F.C.O., H.Z., F.P.), Max Delbrück Center for Molecular Medicine and Charité - Universitätsmedizin Berlin, Corporate Member of Freie Universität Berlin and Humboldt-Universität zu Berlin; Einstein Center Digital Future (H.Z.), Berlin; Department of Neurology (P.A., M.R.), Medical Faculty; Department of Neurology (M.R.), Center for Neurology and Neuropsychiatry, LVR-Klinikum, Heinrich-Heine University Düsseldorf; Department of Neurology (P.A.), Maria Hilf Clinics, Mönchengladbach; Department of Ophthalmology (C.B., N.F.), Klinikum rechts der Isar, TUM School of Medicine, Technical University of Munich, Germany; Department of Ophthalmology (J.P.), University of Basel, Switzerland; Airport Munich Eye Clinic MVZ (N.F.), Germany; Department of Ophthalmology (J.P.), University of Basel, Switzerland; Institute of Clinical Neuroimmunology (J.H., J.A.G.), LMU Hospital, Ludwig-Maximilians-Universität München, Munich; Department of Ophthalmology (C.M.), Universitätsklinikum Erlangen, Friedrich-Alexander-Universität Erlangen-Nürnberg, Erlangen, Germany; Department of Neurology (E.S.V., P.A.C., S.S.), Johns Hopkins University School of Medicine, Baltimore, MD; Department of Neuroscience (A.V.D.W.), Central Clinical School, Monash University, Melbourne, Victoria, Australia; Department of Neurology (O.A.-L.), Cedars-Sinai Medical Center, Los Angeles, CA; Servicio de Neurología (S.C., A.V.-J.), Centre d'Esclerosi Múltiple de Catalunya (Cemcat), Hospital Universitari Vall d'Hebron, Universitat Autònoma de Barcelona, Spain; Department of Neurology with Institute of Translational Neurology (J.K., H.W.), University Hospital Münster, Germany; Department of Neurology (J.L.P.), First Medical Faculty, Charles University and General University Hospital in Prague, Czech Republic; National Institute for Health and Care Research (NIHR) University College London Hospitals (UCLH) Biomedical Research Centre (BRC) (O.C.), United Kingdom; Ophthalmology Department (E.G.-M.), Miguel Servet University Hospital, Aragones Institute of Health Sciences, Zaragoza, Spain; Department of Neurology (V.K.), University Hospital Zurich, Switzerland; Moorfields Eye Hospital and The National Hospital for Neurology and Neurosurgery (A.P., A.T.T.), University College London, United Kingdom; and Department of Neurology (A.P.), Amsterdam UMC, Vrije Universiteit Amsterdam, MS Centre and Neuro-ophthalmology Expertise Centre Amsterdam, Amsterdam Neuroscience, Netherlands.

Go to [Neurology.org/NN](https://www.neurology.org/NN) for full disclosures. Funding information is provided at the end of the article.

The Article Processing Charge was funded by the authors.

This is an open access article distributed under the terms of the Creative Commons Attribution-NonCommercial-NoDerivatives License 4.0 (CC BY-NC-ND), which permits downloading and sharing the work provided it is properly cited. The work cannot be changed in any way or used commercially without permission from the journal.

## Glossary

**DVC** = deep vascular complex; **GCIP** = ganglion cell and inner plexiform layer; **MAS** = motion artifact score; **NMOSD** = neuromyelitis optica spectrum disorders; **OCT** = optical coherence tomography; **OCTA** = optical coherence tomography angiography; **PAR** = projection artifact removal; **QC** = quality control; **ROI** = region of interest; **SVC** = superficial vascular complex; **TUM** = Technical University of Munich; **UCL** = University College London.

interrater kappa was substantial ( $\kappa$  0.67). Projection artifacts were the main reason for interrater disagreement. Because artifacts can affect only parts of OCTA images, we agreed that prior definition of a specific region of interest (ROI) is crucial for subsequent OCTA quality assessment. To enhance artifact recognition and interrater agreement on reduced image quality, we designed a scoring guide and OCTA training set. Using these educational tools, 23 raters from 14 different centers reached an almost perfect agreement ( $\kappa$  0.92) for the rejection of poor-quality OCTA images using the OSCAR-MP criteria.

## Discussion

We propose a 3-step approach for standardized quality control: (1) To define a specific ROI, (2) to assess the occurrence of OCTA artifacts according to the OSCAR-MP criteria, and (3) to evaluate OCTA quality based on the occurrence of different artifacts within the ROI. OSCAR-MP OCTA QC criteria achieved high interrater agreement in an international multicenter study and is a promising QC protocol for application in the context of future clinical trials and studies.

## Introduction

Inner retinal layer thinning is a frequent finding in various autoimmune diseases of the CNS such as multiple sclerosis (MS)<sup>1</sup> and neuromyelitis optica spectrum disorders (NMOSD).<sup>2</sup> Loss of retinal nerve fibers and ganglion cells is also regularly found in ophthalmologic disorders such as glaucoma<sup>3</sup> and in the context of systemic comorbidity such as diabetes mellitus<sup>4</sup> or hypertension.<sup>5</sup> In this context, a noteworthy distinction arises from the frequent and easily detectable disruptions in retinal architecture during funduscopy, setting it apart from cases of MS or NMOSD. Notably, glaucoma often manifests with an elevated vertical cup-to-disc ratio, whereas common alterations associated with diabetic or hypertensive retinopathy include hemorrhages, exudates, and macular or optic disc edema.<sup>3-5</sup> Optical coherence tomography (OCT) allows high-resolution visualization of the retinal anatomy and has turned to a standard imaging modality in ophthalmology since more than 2 decades. For several years, the OCT technique has also been used in neurology, especially in patients with demyelinating diseases such as MS and is about to enter clinical routine diagnostic workup: here, different measures, particularly thinning of the combined ganglion cell and inner plexiform layer (GCIP), have been linked to neurodegenerative processes of the CNS and worse disease prognosis. GCIP atrophy irrespective to a history of optic neuritis has been linked to a higher risk of ongoing disease activity and disability progression in patients with MS.<sup>6-10</sup> Moreover, adding the optic nerve region assessed by retinal OCT to the diagnostic criteria of MS might improve the diagnostic sensitivity of the McDonald diagnostic criteria of MS.<sup>11</sup> In this context, a standardized and easily applicable approach for OCT quality control (QC) is mandatory. The OSCAR-IB consensus criteria for OCT QC that consist of obvious problems (O), signal strength (S), wrong centration (C), algorithm failure (A), retinal pathology other than MS related (R), illumination (I), and beam placement (B) have been

proposed in 2012, internationally validated, and included in current OCT reporting guidelines.<sup>12-14</sup>

OCT angiography (OCTA), a functional extension of the conventional OCT technique, facilitates rapid, noninvasive, and high-resolution imaging of sufficiently perfused retinal blood vessels.<sup>15</sup> OCTA is increasingly used for the diagnosis and monitoring of ophthalmologic disorders such as age-related macular degeneration,<sup>16</sup> diabetic retinopathy,<sup>17</sup> and glaucoma.<sup>18</sup> There is growing evidence that patients experiencing CNS autoimmune diseases also reveal alterations of the retinal vasculature. During MS, rarefaction of the superficial vascular complex (SVC), which supplies the retinal nerve fiber layer and GCIP, is evident in eyes with and without a history of optic neuritis and has been found to be associated with worse visual function, disability, and prognosis.<sup>19-22</sup>

OCTA image acquisition may be challenging in patients with visual disability due to the long image acquisition time of up to 20 minutes per eye. Consequently, OCTA image quality varies substantially. Poor image quality reduces the interpretability and comparability of data; hence, QC is crucial for quantitative and qualitative analyses of images.<sup>23,24</sup>

To date, comprehensive and validated criteria for OCTA image quality assessment and detection of artifacts are not available. This study aimed to develop and validate reliable and easy-to-use consensus criteria for OCTA QC.

## Methods

### Study Design

In the first step, we performed a thorough literature review on OCTA imaging artifacts and image quality. R.W., C.N., and

B.K. reviewed the English and German literature of all studies focusing on “optical coherence tomography angiography” between the first report in 2014<sup>25</sup> and 2021 including manuscripts published ahead of print. We searched PubMed and Web of Science for OCTA and refined the search terms by “artifacts,” “error,” “quality,” “quality control,” “quality assessment,” and “signal strength.” The results were used to define different types of OCTA imaging artifacts and patterns that affect OCTA image quality.

In the second step, we obtained a set of 40 OCTA scans from patients with MS (30 OCTA), Sjogren syndrome (3 OCTA), and uveitis (1 OCTA) and healthy individuals (6 OCTA) including 2 two-dimensional (2D) en face images of the superficial and deep vascular complex (DVC) of the perifoveal macula with varying image quality. OCTA were selected randomly from 2 ongoing prospective cohorts at the Technical University of Munich (TUM) from 2018 to 2021 and University College London (UCL) in 2021. The OCTA scans were rated independently by 7 trained and experienced raters (R.W., L.A., C.N., E.W., E.F.R., B.K., and C.Y.) for the occurrence of different types of artifacts and quality problems. Scans failing 1 or more different criteria were rated as “reject.” We calculated Fleiss kappa statistics to assess the interrater agreement on the occurrence of quality criteria and the decision to reject the respective image.

In the third step, the results were analyzed to identify the main sources and reasons for disagreement. We (R.W., C.Y., B.K., A.P., A.T., and S.S.) discussed and identified different adaptations to improve the applicability of the OCTA quality assessment criteria. After meeting a consensus, the original QC criteria were revised accordingly.

In the fourth and final step, the revised OCTA quality criteria underwent international multicenter validation. For this purpose, we prepared a detailed manual on different types of OCTA artifacts and quality issues (“scoring guide”), a training set of 15 annotated and commented OCTA images (“training set,” see eMethods, [links.lww.com/NXI/A918](https://links.lww.com/NXI/A918)), and a new scoring set of 10 perifoveal OCTA images (“scoring set”). All the 127 members of the International Multiple Sclerosis International Visual System Consortium (IMSVISUAL) were invited once through email to participate. It was left to the respective centers to select a suitable person to assess the images, and there were no specific qualification requirements. All raters were asked to work through the OCTA scoring guide and training set before rating all images from the scoring set. Again, all scans were rated for the occurrence of different types of artifacts or quality issues and rejected when failing 1 or more QC criteria. All raters were asked to answer a standardized survey. Besides information on the local existing infrastructure, participants were asked to provide information on how much time was spent working through the OCTA scoring guide and training set and how the participants self-assessed their experience in interpreting OCT and OCTA images (scale 1 to 7, 1 = beginner, 7 = professional).

Afterward, Fleiss kappa statistics for interrater agreement were calculated.

## Standard Protocol Approvals, Registrations, and Patient Consents

The study was approved by the respective ethics committees of the TUM, School of Medicine (116/16 S) and UCL (19/WA/0157) and adhered to the Declaration of Helsinki. All participants and patients undergoing OCTA analysis provided written informed consent.

## Optical Coherence Tomography Angiography

OCTA examinations were acquired from both undilated eyes of each patient or healthy individual under low-lighting conditions using a spectral domain OCT with angiography module (Heidelberg Engineering Spectralis OCT2) by experienced technicians as previously described.<sup>19</sup> En face images and decorrelation signals were recorded within a 2.9 × 2.9-mm area (512 B-scans) focusing on the fovea centralis with the eye tracking function enabled. Segmentation of the macular area was performed automatically by the in-built software (v2.5.4) into the SVC and DVC.

## Statistical Analysis

Fleiss Kappa values were calculated using Excel 365 (Microsoft).<sup>26</sup> The level of agreement was rated as slight (0–0.20), fair (0.21–0.40), moderate (0.41–0.60), substantial (0.61–0.80), or almost perfect (0.81–1.00).<sup>27</sup> Differences between different rating groups in time amounts spent were calculated with GraphPad Prism (v9.5.1) using an unpaired *t* test if normally distributed or a nonparametric Mann-Whitney *U* test if not. Values were provided as mean ± SD if normally distributed, otherwise as median and interquartile range (IQR, 25%–75%). An alpha of <0.05 was accepted as significant.

## Data Availability

The “scoring guide” and “scoring set” are available on reasonable request. We will share raw imaging OCT-A data in an anonymized way on request by any qualified investigator. Data are not publicly available due to privacy or ethical restrictions.

## Results

### Step 1: Identification of OCTA Image Quality Indicators

After a thorough literature review, 7 criteria were identified as crucial for OCTA image quality. The criteria are summarized by the mnemonic “OSCAR-MP” and are described in detail in Table 1. Examples for obvious problems (O) including tilting and defocus and centration artifacts (C) are visualized in Figure 1. Low levels of signal strength (S) affect OCTA quantitative measures and OCTA reproducibility. Different manufacturer suggestions for sufficient signal strength are summarized in eTable 1 ([links.lww.com/NXI/A919](https://links.lww.com/NXI/A919)). In most OCTA devices, landmarks of different vascular plexus are defined by certain retinal layers such as the

inner limiting membrane, the inner plexiform layer, or the retinal pigment epithelium. Thus, underlying B-scans should be checked for algorithm (A) segmentation failure (Figure 2A). Retinal pathology (R) like cysts or retinal edema might affect accurate retinal layer segmentation and go along with concomitant segmentation algorithm failure (Figure 2B). Due to the physical principle of OCTA, motion (M) and projection (P) artifacts are distinctive for the OCTA technique and are only rarely found in conventional OCT. Eye movements regularly result in different types of motion (M) artifacts (Figure 3). Blink lines (Figure 3A) and displacement (Figure 3B) result from eye movements during OCTA examination. Further types of OCTA motion artifacts result from eye movement and subsequent software correction by the OCTA device such as stretching (Figure 3C), vessel doubling (Figure 3D), or banding (Figure 3E). Finally, projection (P) artifacts mostly affect deeper retinal layers due to the projection of larger and superficial vessels (for example, from the SVC) into deeper and smaller retinal vessels (such as the DVC) (positive projection artifact) (Figure 3F). In most devices, projection artifacts are removed by software algorithms implemented in the manufacturer's OCTA software. These algorithms, however, may cause projection artifacts as well by excessive and immoderate removal of superficial vessel signals (negative projection artifact) (Figure 3F).

## Step 2: Application of the OSCAR-MP Consensus Criteria

After the identification of different OCTA image quality indicators, we challenged the application of the OSCAR-MP criteria in both clinical and scientific use. We obtained a set of 40 OCTA images of different quality incorporating 2D en face images of the SVC and DVC of the perifoveal macula (30 MS, 3 Sjogren syndrome, 1 uveitis, and 6 healthy individuals). These OCTA images were evaluated by 7 experienced raters.

**Table 1** The OSCAR-MP QC Criteria for Retinal OCTA Scans

<b>O</b>	Obvious problems not covered by the items below Focus, defocus, beam placement, illumination, opacities, shadowing
<b>S</b>	Signal strength Consider device-specific thresholds for signal strength
<b>C</b>	Centration Evaluate correct placement of the scanning area depending on the region of interest
<b>A</b>	Algorithm failure Evaluate accurate segmentation of the different vessel plexus
<b>R</b>	Retinal pathology Check the presence of any retinal pathology and evaluate whether it impairs the analysis of the retinal vasculature
<b>M</b>	Motion artifacts Evaluate different types of motion artifacts and estimate the affected proportion of the image
<b>P</b>	Projection artifacts Search for projection artifacts of superficial vessels into deeper layers

We found a substantial interrater agreement to reject an OCTA image due to poor image quality ( $\kappa = 0.67$ , frequency of observation 0.85). The level of agreement was substantial to almost perfect for most OSCAR-MP items (obvious problems  $\kappa = 0.65$ , frequency of observation 0.60, signal strength  $\kappa = 0.87$ , frequency of observation 0.05, centration  $\kappa = 0.70$ , frequency of observation 0.28, algorithm failure  $\kappa = 1.0$ , frequency of observation 0, retinal pathology  $\kappa = 1.0$ , frequency of observation 0.03, motion artifacts  $\kappa = 0.70$ , and frequency of observation 0.65) but poor for projection artifacts ( $\kappa = 0.16$ , frequency of observation 0.03).

## Step 3: REVISION and Definition of the OSCAR-MP Consensus Criteria

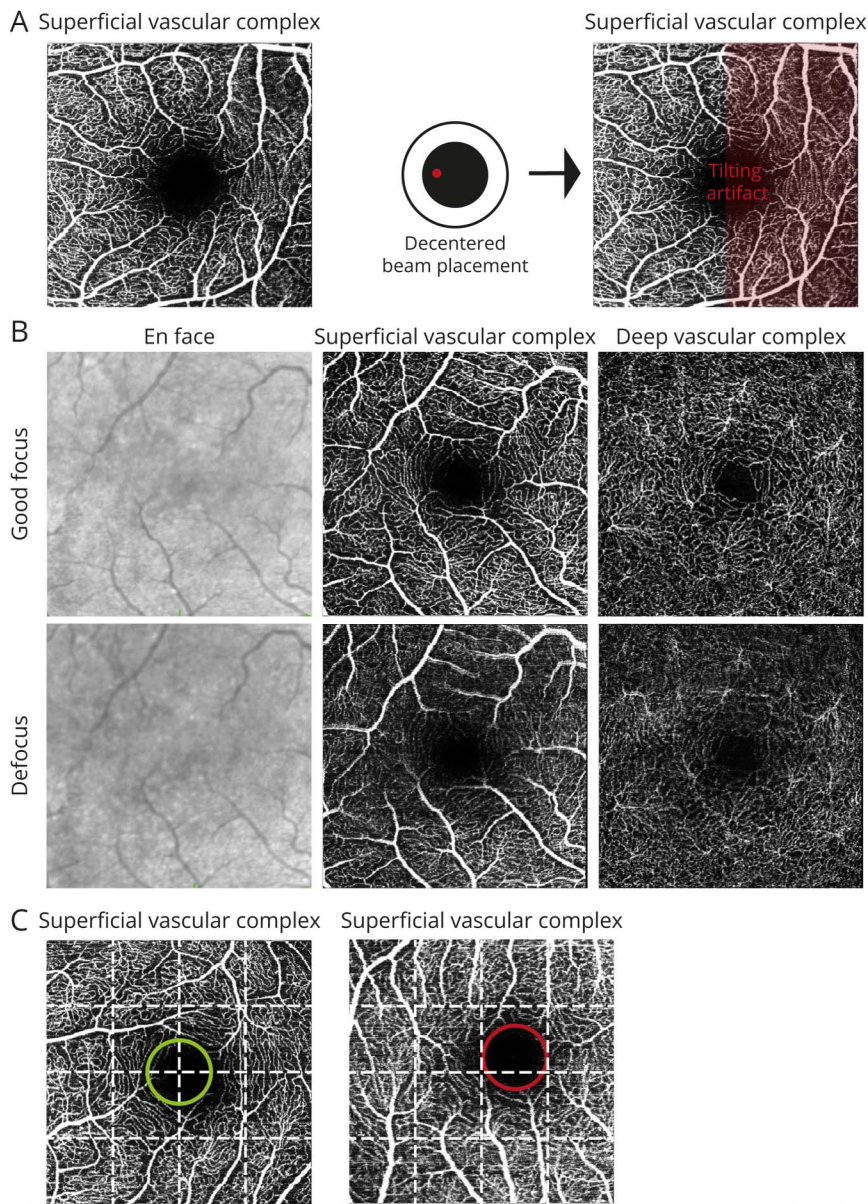
These results were evaluated in detailed discussions to simplify and improve the clinical application of the OSCAR-MP criteria. Because different types of OCTA image artifacts and quality issues may affect different regions of the image, there was the consensus to define a specific region of interest (ROI) in advance and to assess the OSCAR-MP criteria within the ROI afterward (Figure 4). Furthermore, we recognized that 6 of 7 OSCAR-MP items affect the superficial and deep retinal vasculature in a comparable manner. Based on this, there was a consensus to assess the SVC for the OSCAR-M items and to assess the deep retinal vasculature (DVC) essentially for the occurrence of projection (P) artifacts. Minor and discrete motion artifacts are regularly observed in both patients and healthy controls and may not necessarily affect OCTA image quality.<sup>28-30</sup> This is especially the case for quilting and blink lines, and those types of "benign" artifacts affect  $\leq 25\%$  of the image (Figure 3E, left). If major motion artifacts such as vessel doubling, stretching, and displacement occur additionally,  $>25\%$  of the OCTA image quality is regularly affected (Figure 3E, right). The expert consensus was to accept OCTA images with motion artifacts in  $\leq 25\%$  of the whole image and to reject OCTA examinations with motion artifacts in  $>25\%$  of the image area.

Consequently, the suggestion was to define the ROI, assess the occurrence of different imaging artifacts and image quality issues using the OSCAR-MP criteria, and then integrate the ROI and the OSCAR-MP ratings into a final OCTA quality assessment (Figure 4).

## Step 4: Multicenter Validation of the OSCAR-MP Consensus Criteria

In the final step, we aimed to validate the OSCAR-MP consensus criteria within an international multicenter setting. All members of the International Multiple Sclerosis International Visual System Consortium (IMSVISUAL) were invited to participate. As summarized in Table 2, a total of 23 raters from 14 different centers with different specialties participated in this study. Ten participants were categorized as having low OCTA experience (self-assessment score  $<4$ , median score 1 (1–2)) and 13 as having high OCTA experience (score  $\geq 4$ , median score 5 (5–6)). Participants with low and high OCTA experience spent comparable amounts of time working through the training

**Figure 1** Obvious Problems (O) and Centration Artifacts (C)



Different examples for obvious problems: (A) A poorly centered beam placement during OCTA acquisition may cause tilting artifacts. Tilting causes a symmetric decrease of vessel densities in the affected area as marked in red. (B) Defocus (lower panel) of the retinal area of interest severely affects image quality and analysis of vessel densities in comparison with the images with good focus (upper panel). (C) OCTA images are mostly centered on the region of interest, which mostly reflects the fovea or optic disc (not shown). Correct centering, by making use of defined landmarks, is important for comparison of different measures. Dividing the image into 4 vertical and horizontal sections might be helpful for evaluation of correct (left panel) and incorrect (right panel) centration. OCTA = optical coherence tomography angiography.

material before performing the OCTA quality assessment (low OCTA experience median 76 minutes (45–76), high OCTA experience 45 minutes (45–76),  $p = 0.36$ ).

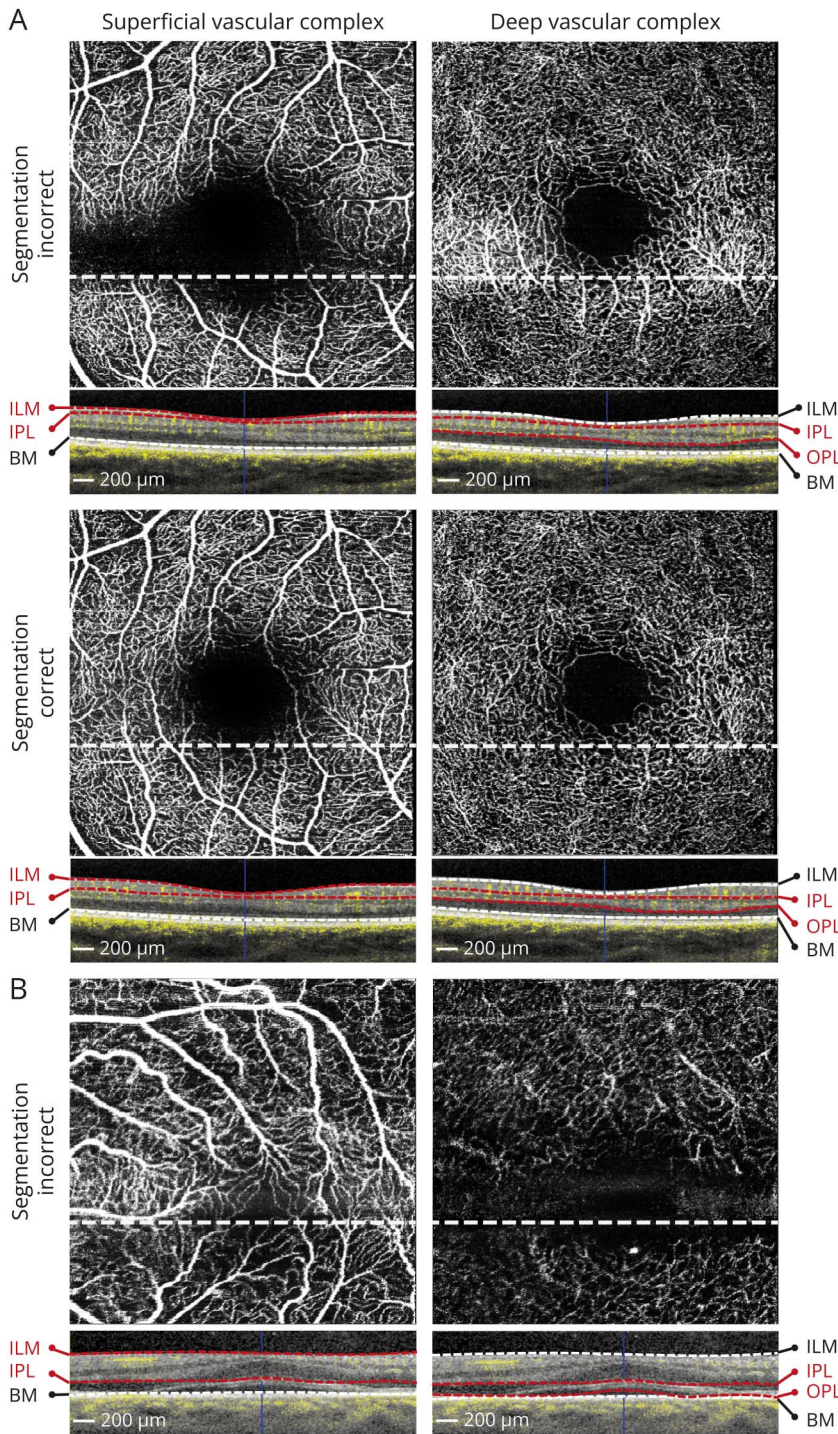
There was an almost perfect agreement to reject any OCTA image due to poor image quality ( $\kappa = 0.92$ , Table 3). The interrater agreement was very high over most OSCAR-MP items including projection artifacts ( $k > 0.80$ ) and substantial for motion artifacts ( $\kappa = 0.77$ ) (Table 3). There were no differences in interrater agreements between neurologists (image rejection  $\kappa = 0.93$ ) or ophthalmologists (image rejection  $\kappa = 0.88$ ). Of note, interrater agreements were comparable between raters with high OCTA experience and low OCTA experience due to self-assessment after thorough education and instruction of the OSCAR-MP criteria.

## Discussion

OCTA is a relatively novel technique allowing the investigation of retinal vessel pathology in various ophthalmologic and neurologic diseases. In this study, we propose the OSCAR-MP criteria for quality control of OCTA images in the field of neurologic and ophthalmologic diseases. Our criteria incorporate most of the OCTA image quality features as described in the scientific literature and are easily applicable and reliable in the context of a multicenter study setting.

Based on the OSCAR-IB criteria, which were published in 2012 and are currently used in most studies applying retinal OCT in neurologic diseases, the OSCAR-MP criteria represent a related extension for OCTA. Of note, both motion (M)

**Figure 2** Algorithm Failure (A) and Retinal Pathology (R)



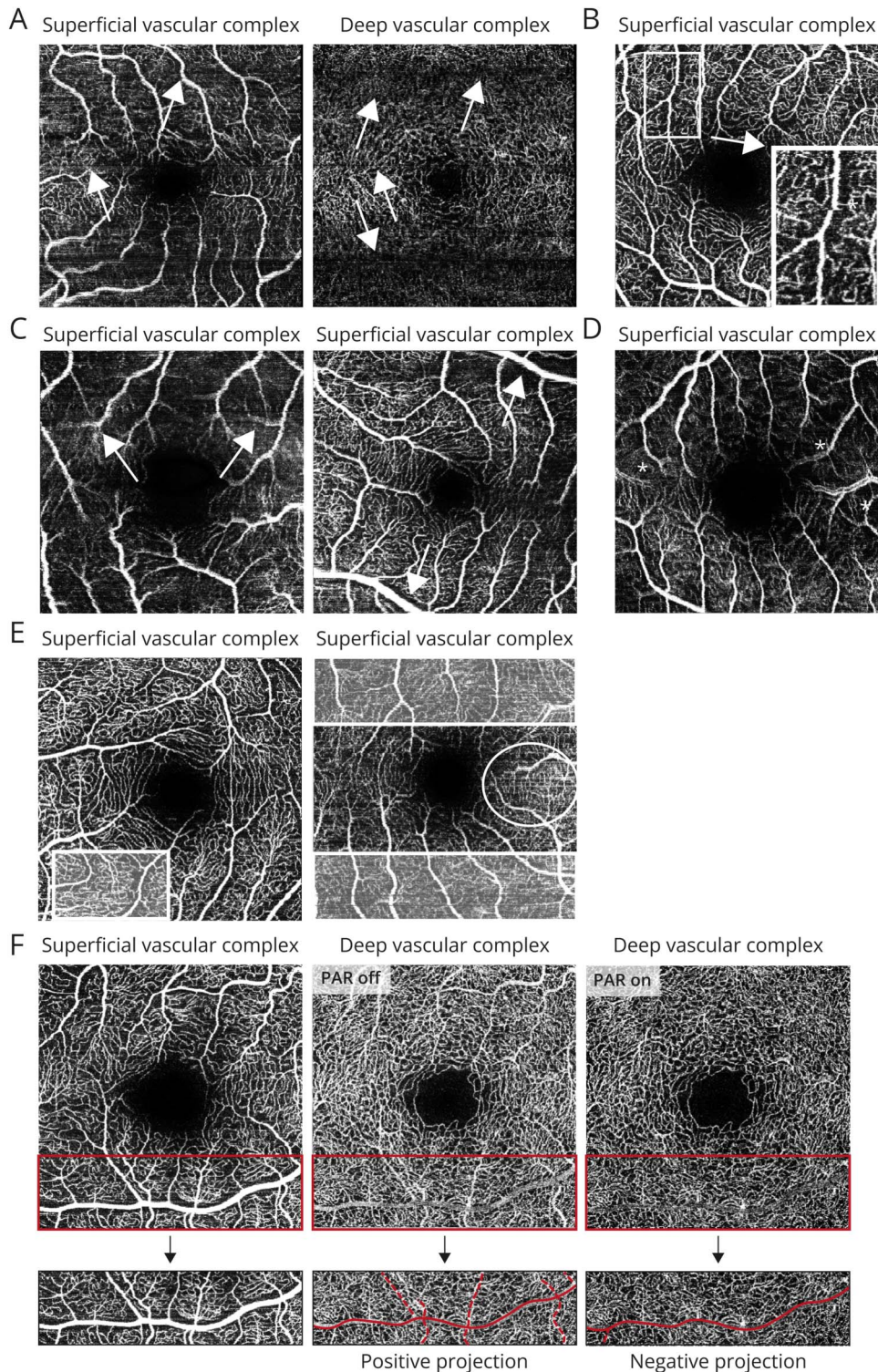
(A) The superficial vascular complex (left) is located and defined between the inner limiting membrane (ILM) and the inner plexiform layer (IPL) and the deep vascular complex (right) between the IPL and the outer plexiform layer (OPL). Segmentation errors due to incorrect identification of the respective layer borders within the B-scan may result in distorted vessel density measures (upper row). Manual correction of segmentation errors restores attribution of vessel signals to the different vascular complexes (lower row). (B) Retinal pathology (central macular edema) as detected in the OCT B-scan may affect retinal layer segmentation accuracy with wrong assignment of the ILM, IPL, and OPL resulting in incorrect and skewed visualization of the retinal vasculature.

and projection (P) artifacts occur frequently during OCTA but rarely during conventional OCT analysis making adaptation and extension of the OSCAR-IB criteria necessary.

We included raters with different medical specialties and various levels of experience in the interpretation of OCTA images. After adequate training on OCTA image quality issues and artifacts, performed by self-study, we report substantial to

almost perfect interrater agreements on the identification of different types of OCTA artifacts irrespective of medical specialty and preexisting experience with OCTA rating. This suggests that the OSCAR-MP criteria for OCTA quality assessment are practical, applicable, and easy to learn by medical professionals across various specialties. Furthermore, it highlights the value of training data sets such as the one used in this study.

**Figure 3** Motion Artifacts (M) and Projection Artifacts (P)



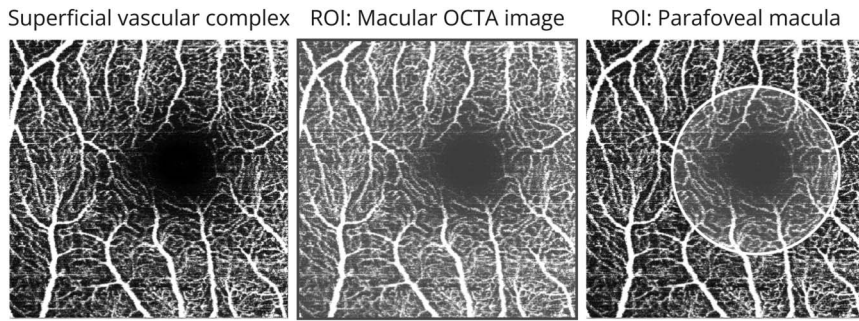
Motion artifacts due to eye movement (A–B) and motion artifacts due to eye movement and software correction (C–E): (A) Blink lines are caused by missing imaging information due to blinking as marked by white arrows; (B) Vessel displacement (asterisk) results from a shift in fixation and eye movements. (C) Vessels appear stretched and flattened particularly at the edge of OCTA image (right) as stretch artifacts (white arrows); (D) vessel doubling (asterisk); (E) Artifacts with adjacent horizontal stripes or bands of different brightness are called banding (white squares); quilting can be described as a rectangular, checkerboard, or crisscross pattern of black and/or white horizontal and vertical lines (white circle). Motion artifacts may appear in smaller areas ( $\leq 25\%$  of the image area, left) and larger areas ( $>25\%$  of the image area, right). (F) Projection artifacts mostly affect deeper layers due to projection of superficial and bigger vessels. The vessel in the lower half of the SVC (left image) can be observed in the DVC when no projection artifact removal (PAR) software is used (PAR off, middle panel). Software-based removal of the superficial vessel exclude information about the DVC vessels in this area and are called negative projections (PAR on, right panel). DVC = deep vascular complex; OCTA = optical coherence tomography angiography; SVC = superficial vascular complex.

For the first of the OSCAR-MP criteria (O – Obvious problems), OCTA scans were rejected because of highly apparent issues that are easily detectable on 2D en face images. These include defocus, incorrect beam placement with tilting, shadowing, and opacities originating from the anterior segment or vitreous.<sup>12,31-33</sup> These artifacts also influence

conventional OCT analysis and have been shown to adversely affect OCTA image quality and quantitative analysis.<sup>29</sup>

Low levels of signal strength (S) can affect OCTA image quality and manufacturers suggest thresholds for sufficient signal strength that should be considered when using OCTA.<sup>23,24,28,34</sup>

**Figure 4** OSCAR-MP Based on Region of Interest



In the image on the left, major motion artifacts and severe decentration are evident; if the whole image is defined as region of interest (ROI), the image should be excluded (middle), and if the parafoveal area is defined as ROI (right), the image might be accepted for further analysis.

Of note, signal strength may still affect quantitative measures even if signal strength measures are above the manufacturer-suggested threshold. Some quantitative measures, such as retinal vessel densities, may increase when improving signal strength.<sup>23,35</sup> Thus, absolute values for OCTA signal strength might be considered when applying the OCTA technique in multicenter or longitudinal studies.

To allow comparability and reproducibility of quantitative OCTA images, the positioning of the scanning frames according to different anatomical landmarks is crucial. Scanning frames are mostly centered on the optic nerve head or

the fovea. Centration artifacts (C) occur during OCTA analysis to varying frequencies depending on whether the scanning frames are positioned manually or automatically by the OCTA device. Centration artifacts are less relevant when the ROI focuses on smaller portions of the scanning area (e.g., the foveal avascular zone) but are critical if larger areas are evaluated (e.g., the whole perifoveal macula).<sup>22</sup> We suggest confirming the accurate centration in every OCTA image since technical aspects like beam placement might affect quantitative OCTA measures depending on whether the ROI occurs in the center or border areas of the respective OCTA image.

**Table 2** Participating Centers Within the IMSVISUAL Network, Specialty, and Number of Raters

Center	Specialty	Number of raters
Baltimore (John Hopkins)	N/A (postdoctoral researcher)	1
Barcelona (Cemcat)	N/A (postdoctoral researcher)	1
Berlin (Charité)	N/A (postdoctoral researcher)	2
Duesseldorf	Neurology	2
Erlangen	Ophthalmology	1
London (UCL)	Neurology	2
Los Angeles (Cedars Sinai)	Neurology	1
Melbourne (Alfred Health)	Neurology	1
Muenster	Neurology	1
Munich (LMU)	Neurology	1
Munich (TUM)	Neurology	4
	Ophthalmology	3
Prague (Charles university)	Neurology	1
Zaragoza	Neuro-ophthalmology	1
Zurich	Neurology	1

Abbreviation: N/A = not applicable.

Algorithm failure (A) with incorrect segmentation of different retinal layers such as the inner limiting membrane, the inner plexiform layer or the retinal pigment epithelium and subsequent inaccurate mapping of blood flow signals to the retinal vascular plexus is an important problem.<sup>36,37</sup> This is of particular relevance for OCTA images incorporating retinal pathologies. Different studies have shown that pathologic features disrupting the retinal architecture may severely affect the segmentation and OCTA image quality.<sup>37,38</sup> While major segmentation errors result in visible deterioration of 2D en face images and are thus very likely recognized by the experienced OCTA reader, minor segmentation errors might be overseen. Thus, assessment of accurate retinal layer segmentation within different B-scans is mandatory to assure correct segmentation.

Retinal pathologies (R) possibly affecting both the retinal layer architecture and vasculature need to be considered when interpreting OCTA images.<sup>23,29</sup> Especially in neurologic diseases such as MS, NMOSD, or Parkinson disease, mild alterations of the retinal vasculature are evident and might be affected significantly by concomitant retinal diseases.<sup>20,39,40</sup> In research settings, we suggest the exclusion of OCTA images with retinal pathologies different from the disease entity primarily studied by OCTA.

Detection and differentiation of motion artifacts (M) may become challenging, especially in persons with limited OCTA



**Table 3** Intercenter Kappas for Each of the Individual OSCAR-MP Items

QC criterion	All raters (n = 23)	Specialty neurology (n = 14)	Specialty ophthalmology (n = 4)	High OCTA experience (n = 13)	Low OCTA experience (n = 10)
<b>O</b>	0.842	0.889	0.733	0.864	0.840
<b>S</b>	0.986	0.974	1.000	0.985	0.953
<b>C</b>	0.884	0.856	0.950	0.938	0.822
<b>A</b>	0.983	0.986	0.950	1.000	0.964
<b>R</b>	0.983	0.971	1.000	1.000	0.960
<b>M</b>	0.773	0.858	0.783	0.803	0.767
<b>P</b>	0.892	0.876	0.950	0.972	0.798
<b>Reject image</b>	0.917	0.933	0.883	0.933	0.891

experience levels. Different scoring systems have been suggested to evaluate motion artifact severity in the literature. The motion artifact score (MAS) differentiates between minor artifacts such as quilting that do not disrupt the retinal vasculature and major artifacts such as displacement, vessel doubling, or stretching that can severely affect the imaging of retinal vessels.<sup>41</sup> Slight to moderate quilting (in up to 2 quadrants of the OCTA images, according to an MAS of 1–2) may regularly occur in high-quality OCTA images of healthy controls with sufficient signal strength and might be acceptable for both qualitative and quantitative OCTA analyses.<sup>28,42</sup> Major artifacts disrupting the retinal vasculature, however, frequently occur in OCTA images of patients with retinal pathologies (according to an MAS of 3 and 4).<sup>42</sup> The MAS has shown to be easily applicable across different levels of OCTA expertise and clinical specialty.<sup>43,44</sup> Other colleagues classified “major” OCTA artifacts as imaging artifacts that disrupt >25% of the retinal architecture. OCTA images with “major” artifacts revealed lower vessel density measures when compared with high-quality OCTA examinations with lower artifact load.<sup>22</sup> The currently suggested approach to reject OCTA images with obvious motion artifacts in >25% of the OCTA images integrates and simplifies both described scoring systems. This approach, however, might reject OCTA images with nonsignificant artifacts (e.g., slight to moderate quilting) in >25% of the image area (according to an MAS of 2) that would otherwise be rated acceptable when using the MAS score. The differentiation between slight, moderate, and significant quilting according to the MAS, however, might be challenging for operators with low OCTA experience. We decided to use a lower threshold to reject OCTA images due to motion artifacts because the aim of our study was to provide a sensitive approach to detect OCTA imaging artifacts.

Projection artifacts (P) regularly occur during OCTA analysis across different types of OCTA devices and manufacturers. Different software algorithms have been used and proposed to remove projection artifacts. During OCTA in neurologic diseases, projection artifacts need to be considered when

evaluating deeper retinal vessel structures (such as the DVC) and are less relevant and abundant when focusing on superficial vessels or retinal areas with preexisting low vessel densities such as the foveal avascular zone.

OCTA represents a significant advance in neuro-ophthalmic vascular imaging due to its noninvasive nature, high precision, and image depth. The ability to visualize and quantify vascular alterations in specific retinal layers might allow for expanded exploration of disease pathogenesis, disease progression, and treatment options. In people with MS, reduced vessel densities of the SVC are frequently found.<sup>45</sup> In eyes with acute ON, SVC vessel loss occurs concomitantly with atrophy of the inner retinal layers after optic neuritis. This observation led to the hypothesis that alterations of the SVC are secondary metabolic effects of retinal ganglion cell loss during ON.<sup>19</sup> In eyes of patients with MS without an ON history, however, vessel rarefaction within the SVC might be linked to a proinflammatory intrathecal immune phenotype and poor disease prognosis irrespective to retinal ganglion cell atrophy.<sup>19</sup> Furthermore, in eyes of patients with NMOSD, diminished SVC vessel densities are associated with increased markers of astrocyte damage and poor visual acuity.<sup>40</sup> These data suggest that OCTA could potentially aid in monitoring subclinical disease activity and might inform novel hypotheses of the underlying pathophysiology leading to alterations of retinal vessels. OCTA relies on repeated B-scans, as alterations occur primarily in areas of motion. Consequently, limitations arise from imaging artifacts, which can undermine measurement reliability and lead to misinterpretation. Implementing consistent OCTA QC criteria such as OSCAR-MP could improve the reliability and comparability of OCTA results across different research institutions. The application of the OSCAR-MP criteria is simple and reliable, especially for scientific use. The detailed and strict application in daily clinical practice, however, may encounter limitations. Against this background, the OSCAR-MP could provide a useful basis for creating automated quality control tools based on artificial intelligence and machine learning in the future.

Our study has several limitations. We used OCTA images exclusively derived from the Heidelberg Engineering Spectralis OCT 2 device and did not consider devices from other manufacturers. OCTA imaging artifacts and quality issues, however, appear across all manufacturers, and the frequency of certain artifact types might vary.<sup>28</sup> Further studies are needed to validate the OSCAR-MP criteria in OCTA images derived from devices of other manufacturers. Furthermore, we applied OCTA images of the parafoveal macula and did not focus on OCTA images of the peripapillary retina. Most artifacts and quality problems, however, occurring in OCTA examinations across the whole retina are not specific to a certain OCTA scan type.<sup>28</sup> Further studies validating the OSCAR-MP criteria in peripapillary OCTA images would be favorable. Although we have incorporated most of the OCTA QC issues into the OSCAR-MP criteria, their practical benefit for multicenter or longitudinal studies has not yet been evaluated. As mentioned earlier, the OSCAR-MP criteria are relatively strict, particularly for motion artifacts, and might lead to an impractically high rejection rate. However, we speculate that the reproducibility and the interrater agreement in both quantitative and qualitative OCTA measures is significantly higher in high-quality when compared with low-quality OCTA images, as defined by the OSCAR-MP criteria. This aspect and the utility of the OSCAR-MP criteria for clinical and research practice need to be proven in future studies.

After specific training, the OSCAR-MP criteria are applicable across different medical specialties and personal OCTA experience levels. In conclusion, we propose the novel OSCAR-MP QC criteria for the use of OCTA in clinical practice, research, and trials.

## Acknowledgment

The authors thank Mira Radic for her expert assistance during OCTA acquisition and analysis.

## Study Funding

R. Wicklein received an intramural research grant from the Technical University of Munich, School of Medicine, and was supported by the Deutsche Forschungsgemeinschaft (DFG, German Research Foundation) under Germany's Excellence Strategy within the framework of the Munich Cluster for Systems Neurology (EXC-2145 - SyNergy ID 390857198). C. Yam's PhD fellowship is funded by the UCL Queen Square Institute of Neurology and Cleveland Clinic London PhD Neuroscience Fellowship. C. Noll received a research scholarship from the Gemeinnützige Hertie Foundation. L. Aly received travel and research support by Novartis. N. Banze received no funding. E. Feodora Romahn received no funding. E. Wolf received no funding. Bernhard Hemmer received funding for the study by the European Union's Horizon 2020 Research and Innovation Program [grant MultipleMS, EU RIA 733161] and the Deutsche Forschungsgemeinschaft (DFG, German Research Foundation) under Germany's Excellence Strategy within the framework of the Munich Cluster

for Systems Neurology [EXC 2145 SyNergy - ID 390857198]. F.C. Oertel received research support by the National MS Society, American Academy of Neurology and Hertie foundation, all outside of the submitted work. H.G. Zimmermann received intramural funding from the Berlin Center for Translational Vascular Biomedicine (VasBioBerlin). P. Albrecht received no funding. M. Ringelstein received no funding. C. Baumann has no financial disclosures and no conflicting relationship. N. Feucht received no funding. J. Penkava received no funding. J. Havla reports grants from the Friedrich-Baur-Stiftung, Merck, and Horizon. C. Mardin is a medical advisor to Heidelberg Engineering, Heidelberg, Germany, receives lecture honorarium by Heidelberg Engineering, Bayer AG, Leverkusen, Germany, and is partially funded by Federal Ministry of Education and Research and Bavarian Ministry of Health. J.A. Gernert received a research grant from the Deutsche Forschungsgemeinschaft (DFG, German Research Foundation; SFB/TRR 274, ID 408885537). E. Vasieliou did not receive any funding. A. van der Walt did not receive any funding. O. Al-Louzi did not receive any funding. S. Cabello did not receive any funding. A. Vidal-Jordana has received support for contracts Juan Rodes (JR16/00024) and from Fondo de Investigación en Salud (PI17/02162 and PI22/01589) from Instituto de Salud Carlos III, Spain. J. Krämer did not receive any funding. Heinz Wiendl did not receive any funding. J.L. Preiningerova was funded by Charles University Cooperation Program in Neuroscience, and General University Hospital in Prague project MH CZ-DRO-VFN64165.... O. Ciccarelli was funded by NIHR RP-2017-08-ST2-004 and supported by researchers at the National Institute for Health and Care Research (NIHR) University College London Hospitals (UCLH) Biomedical Research Center (BRC) including OC. E. Garcia-Martin received grant support: PI20/00437 (Carlos III Health Institute) and Inflammatory Disease Network (RICORS) (RD21/0002/0050) (Carlos III Health Institute). V. Kana received funding from the Swiss National Foundation and a Filling the Gap protected research time grant (University of Zurich), all outside of the submitted work. P.A. Calabresi reports no funding. F. Paul reports no funding. S. Saidha reports no funding. A. Petzold reports no funding. A. Toosy is supported by recent awards from the MRC (MR/S026088/1), NIHR BRC (541/CAP/OC/818837) and RoseTrees Trust (A1332 and PGL21/10079), and MSIF. B. Knier was funded by the Else Kröner-Fresenius-Stiftung (Else Kröner-Fresenius Exzellenzstipendium 2019\_EKES.09) and the Gemeinnützige Hertie Foundation (medMS program) and received a research award from Novartis.

## Disclosure

R. Wicklein received a poster grant from Novartis; C. Yam reports no conflict of interest; C. Noll reports no disclosures relevant to the manuscript; L. Aly received travel and research support by Novartis; N. Banze reports no disclosures relevant to the manuscript; E.F. Romahn reports no disclosures relevant to the manuscript; E. Wolf reports no disclosures relevant to the manuscript; B. Hemmer has served on scientific advisory

boards for Novartis; he has served as DMSC member for AllergyCare, Sandoz, Polpharma, Biocon, and TG therapeutics; his institution received research grants from Roche for multiple sclerosis research. He has received honoraria for counseling (Gerson Lehrmann Group). He holds part of 2 patents; one for the detection of antibodies against KIR4.1 in a subpopulation of patients with multiple sclerosis and one for genetic determinants of neutralizing antibodies to interferon. All conflicts are not relevant to the topic of the study. He is associated with DIFUTURE (Data Integration for Future Medicine) [BMBF 01ZZ1804[A-I]]; F.C. Oertel reports no disclosures relevant to the manuscript; H.G. Zimmermann received research grants and speaking honoraria from Novartis; P. Albrecht received, with approval of the Rector of Heinrich-Heine University and the CEO of University of Düsseldorf Hospital, personal fees, research grants, and nonfinancial support from Allergan, Biogen, Celgene, Janssen Cilag, Ipsen, Merck Serono, Merz Pharmaceuticals, Novartis, and Roche, personal fees and nonfinancial support from Bayer Healthcare, Teva, and Sanofi-Aventis/Genzyme, grants from the German Research Foundation (DFG) all outside the submitted work; M. Ringelstein received speaker honoraria from Novartis, Bayer Vital GmbH, Roche, Alexion, Horizon, and Ipsen and travel reimbursement from Bayer Schering, Biogen Idec, Merz, Genzyme, Teva, Roche, Horizon, and Merck, none related to this study; C. Baumann reports no disclosures relevant to the manuscript; N. Feucht reports no disclosures relevant to the manuscript; J. Penkava reports no disclosures relevant to the manuscript; J. Havla reports personal fees and nonfinancial support from Alexion, Horizon, Roche, Merck, Novartis, Biogen, BMS, and Janssen and nonfinancial support from the Guthy-Jackson Charitable Foundation and the Sumaira Foundation; J.A. Gernert received travel expenses and nonfinancial support from Merck; C. Mardin is a medical advisor to Heidelberg Engineering, Heidelberg, Germany, receives lecture honorarium by Heidelberg Engineering, Bayer AG, Leverkusen, Germany, and is partially funded by Federal Ministry of Education and Research and Bavarian Ministry of Health; E. Vasileiou reports no disclosures relevant to the manuscript; A. van der Walt served on advisory boards for Novartis, Biogen, Merck, Roche, and NervGen. She received unrestricted research grants from Novartis, Biogen, Merck, and Roche. She is currently a coprincipal investigator on a cosponsored observational study with Roche, evaluating a Roche-developed smartphone app, Floodlight-MS. She has received speaker's honoraria and travel support from Novartis, Roche, Biogen, and Merck. She serves as the Chief operating Officer of the MSBase Foundation (not for profit). Her primary research support is from the National Health and Medical Research Council of Australia and MS Research Australia; O. Al-Louzi has received grant support from the National Multiple Sclerosis Society and American Brain Foundation (FAN-1807-32163) unrelated to the current project; S. Cabello reports no disclosures relevant to the manuscript; A. Vidal-Jordana has engaged in consulting and/or participated as speaker in events organized by Roche, Novartis, Merck, and Sanofi, none of them related to this work; J. Krämer received honoraria for lecturing from Biogen, Novartis, Sanofi

Genzyme, Roche, Mylan, and Teva and financial research support from Sanofi Genzyme, Novartis, Roche, and Amicus Therapeutics; H. Wiendl received compensation for serving on Scientific Advisory Boards/Steering Committees for Bayer Healthcare, Biogen Idec, Sanofi Genzyme, Merck Serono, and Novartis. He has received speaker honoraria and travel support from Bayer Vital GmbH, Bayer Schering AG, Biogen, CSL Behring, EMD Serono, Fresenius Medical Care, Genzyme, Merck Serono, Omniamed, Novartis, and Sanofi Aventis. He has received compensation as a consultant from Biogen Idec, Merck Serono, Novartis, Roche, and Sanofi Genzyme. H. Wiendl also received research support from Bayer Healthcare, Bayer Vital, Biogen Idec, Merck Serono, Novartis, Sanofi Genzyme, Sanofi US, and Teva; J. Lizrova Preiningerova received travel support and speaking honoraria from Roche, Genzyme, Novartis, and Biogen and received a research grant from Biogen; O. Ciccarelli is a member of independent DSMB for Novartis, gave a teaching talk on McDonald criteria in a Merck local symposium, and contributed to an Advisory Board for Biogen; she is Deputy Editor of *Neurology*, for which she receives an honorarium; E. Garcia-Martin has nothing to disclose; V. Kana received travel support from Biogen and speaking honoraria from Merck; P.A. Calabresi is PI on a grant to Johns Hopkins University from Genentech and has received consulting honoraria from Idorsia and Lilly; F. Paul has nothing to disclose; S. Saidha has received consulting fees from Medical Logix for the development of CME programs in neurology and has served on scientific advisory boards for Biogen, Novartis, Genentech Corporation, TG therapeutics, Horizon therapeutics, Rewind therapeutics, and Bristol Myers Squibb. He has performed consulting for Novartis, Genentech Corporation, JuneBrain LLC, and Lapix therapeutics. He is the PI of investigator-initiated studies funded by Genentech Corporation, Novartis, and Biogen. He previously received support from the Race to Erase MS foundation. He has received equity compensation for consulting from JuneBrain LLC and Lapix therapeutics. He was also the site investigator of trials sponsored by MedDay Pharmaceuticals and Clene Pharmaceuticals and is the site investigator of a trial sponsored by Novartis; A. Petzold received grant support for remyelination trials in multiple sclerosis to the Amsterdam University Medicam Centre, Department of Neurology, MS Centre (RESTORE trial) and UCL, London RECOVER trial; fight for Sight (nimodipine in optic neuritis trial); royalties or licenses from Up-to-Date (Wolters Kluwer) on a book chapter; speaker fees for the Heidelberg Academy; participation on Advisory Board SC Zeiss OCTA Angi-Network, SC Novartis OCTiMS study; leadership roles for Governing Board IMSVISUAL (until DEC 2022), Chairman ERN-EYE Neuro-ophthalmology (until OCT 2020), board member of National Dutch Neuro-ophthalmology Association; equipment: OCTA from Zeiss (Plex Elite); medical writing: support from Novartis for manuscript doi: 10.1002/acn3.51473; A. Toosy has received speaker honoraria from Biomedica and Merck and meeting expenses from Biogen Idec and Merck. He was the UK PI for 2 clinical trials sponsored by MEDDAY pharmaceutical company (MD1003 in optic neuropathy [MS-ON - NCT02220244] and

progressive MS [MS-SPI2 - NCT02220244]; B. Knier received travel support and speaking honoraria from Novartis and Teva and served at the advisory board of Merck. He received a research grant from Novartis. Go to [Neurology.org/NN](https://www.neurology.org/NN) for full disclosures.

## Publication History

Received by *Neurology: Neuroimmunology & Neuroinflammation* May 22, 2023. Accepted in final form September 1, 2023. Submitted and externally peer reviewed. The handling editor was Editor Josep O. Dalmau, MD, PhD, FAAN.

## Appendix Authors

Name	Location	Contribution
<b>Rebecca Wicklein, MD</b>	Department of Neurology, Klinikum rechts der Isar, TUM School of Medicine, Technical University of Munich, Germany	Major role in the acquisition of data; analysis or interpretation of data
<b>Charmaine Yam, MD</b>	Department of Neuroinflammation, Queen Square MS Centre, Faculty of Brain Sciences, UCL Queen Square Institute of Neurology, University College London; Neurosciences Institute, Cleveland Clinic London, United Kingdom	Major role in the acquisition of data; analysis or interpretation of data
<b>Christina Noll, MD</b>	Department of Neurology, Klinikum rechts der Isar, TUM School of Medicine, Technical University of Munich, Germany	Major role in the acquisition of data
<b>Lilian Aly, MD</b>	Department of Neurology, Klinikum rechts der Isar, TUM School of Medicine, Technical University of Munich, Germany	Major role in the acquisition of data
<b>Nicolas Banze</b>	Department of Neurology, Klinikum rechts der Isar, TUM School of Medicine, Technical University of Munich, Germany	Major role in the acquisition of data
<b>Eva Feodora Romahn</b>	Department of Neurology, Klinikum rechts der Isar, TUM School of Medicine, Technical University of Munich, Germany	Major role in the acquisition of data
<b>Elisabeth Wolf</b>	Department of Neurology, Klinikum rechts der Isar, TUM School of Medicine, Technical University of Munich, Germany	Major role in the acquisition of data
<b>Bernhard Hemmer, MD</b>	Department of Neurology, Klinikum rechts der Isar, TUM School of Medicine, Technical University of Munich; Munich Cluster for Systems Neurology (SyNergy), Munich, Germany	Major role in the acquisition of data
<b>Frederike C. Oertel, MD, PhD</b>	Experimental and Clinical Research Center, Max Delbrück Center for Molecular Medicine and Charité - Universitätsmedizin Berlin, Corporate Member of Freie Universität Berlin and Humboldt-Universität zu Berlin	Major role in the acquisition of data

## Appendix (continued)

Name	Location	Contribution
<b>Hanna Zimmermann, PhD</b>	Experimental and Clinical Research Center, Max Delbrück Center for Molecular Medicine and Charité - Universitätsmedizin Berlin, corporate member of Freie Universität Berlin and Humboldt-Universität zu Berlin; Einstein Center Digital Future, Berlin, Germany	Major role in the acquisition of data
<b>Philipp Albrecht, MD</b>	Department of Neurology, Medical Faculty, Heinrich-Heine University Düsseldorf; Department of Neurology, Maria Hilf Clinics, Mönchengladbach, Germany	Major role in the acquisition of data
<b>Marius Ringelstein, MD</b>	Department of Neurology, Medical Faculty, Heinrich-Heine University Düsseldorf; Department of Neurology, Center for Neurology and Neuropsychiatry, LVR-Klinikum, Germany	Major role in the acquisition of data
<b>Carmen Baumann, MD</b>	Department of Ophthalmology, Klinikum rechts der Isar, TUM School of Medicine, Technical University of Munich, Germany	Major role in the acquisition of data
<b>Nikolaus Feucht, MD</b>	Department of Ophthalmology, Klinikum rechts der Isar, TUM school of Medicine, Technical University of Munich; Airport Munich Eye Clinic MVZ, Munich, Germany	Major role in the acquisition of data
<b>Josef Penkava, MD</b>	Department of Ophthalmology, Klinikum rechts der Isar, TUM school of Medicine, Technical University of Munich, Munich, Germany; Department of Ophthalmology, University of Basel, Switzerland	Major role in the acquisition of data
<b>Joachim Havla, MD</b>	Institute of Clinical Neuroimmunology, LMU Hospital, Ludwig-Maximilians-Universität München, Munich, Germany	Major role in the acquisition of data
<b>Jonathan A. Gernert, MD</b>	Institute of Clinical Neuroimmunology, LMU Hospital, Ludwig-Maximilians-Universität München, Munich, Germany	Major role in the acquisition of data
<b>Christian Mardin, MD, FEBO</b>	Department of Ophthalmology, Universitätsklinikum Erlangen, Friedrich-Alexander-Universität Erlangen-Nürnberg, Erlangen, Germany	Major role in the acquisition of data
<b>Eleni S. Vasileiou, MD</b>	Department of Neurology, Johns Hopkins University School of Medicine, Baltimore, MD	Major role in the acquisition of data
<b>Anneke Van Der Walt, MBChB PhD</b>	Department of Neuroscience, Central Clinical School, Monash University, Melbourne, Victoria, Australia	Major role in the acquisition of data
<b>Omar Al-Louzi, MD</b>	Department of Neurology, Cedars-Sinai Medical Center, Los Angeles, CA	Major role in the acquisition of data
<b>Sergio Cabello</b>	Servicio de Neurología, Centre d'Esclerosi Múltiple de Catalunya (Cemcat), Hospital Universitari Vall d'Hebron, Universitat Autònoma de Barcelona, Spain	Major role in the acquisition of data

## Appendix (continued)

Name	Location	Contribution
<b>Angela Vidal-Jordana, MD, PhD</b>	Servicio de Neurología, Centre d'Esclerosi Múltiple de Catalunya (Cemcat), Hospital Universitari Vall d'Hebron, Universitat Autònoma de Barcelona, Spain	Major role in the acquisition of data
<b>Julia Krämer, MD</b>	Department of Neurology with Institute of Translational Neurology, University Hospital Münster, Germany	Major role in the acquisition of data
<b>Heinz Wiendl, MD</b>	Department of Neurology with Institute of Translational Neurology, University Hospital Münster, Germany	Major role in the acquisition of data
<b>Jana Lizrova Preiningerova, MD, PhD</b>	Department of Neurology, First Medical Faculty, Charles University and General University Hospital in Prague, Czech Republic	Major role in the acquisition of data
<b>Olga Ciccarelli, MD, PhD</b>	Department of Neuroinflammation, Queen Square MS Centre, Faculty of Brain Sciences, UCL Queen Square Institute of Neurology, University College London; National Institute for Health and Care Research (NIHR) University College London Hospitals (UCLH) Biomedical Research Centre (BRC), United Kingdom	Major role in the acquisition of data
<b>Elena Garcia-Martin, MD, PhD</b>	Ophthalmology Department, Miguel Servet University Hospital, Aragonese Institute of Health Sciences, Zaragoza, Spain	Major role in the acquisition of data
<b>Veronika Kana, MD</b>	Department of Neurology, University Hospital Zurich, Switzerland	Major role in the acquisition of data
<b>Peter A. Calabresi, MD</b>	Department of Neurology, Johns Hopkins University School of Medicine, Baltimore, MD	Major role in the acquisition of data
<b>Friedemann Paul, MD</b>	Experimental and Clinical Research Center, Max Delbrück Center for Molecular Medicine and Charité - Universitätsmedizin Berlin, corporate member of Freie Universität Berlin and Humboldt-Universität zu Berlin, Germany	Major role in the acquisition of data
<b>Shiv Saidha, MBBCh, MD</b>	Department of Neurology, Johns Hopkins University School of Medicine, Baltimore, MD	Major role in the acquisition of data; analysis or interpretation of data
<b>Axel Petzold, MD, PhD</b>	Department of Neuroinflammation, Queen Square MS Centre, Faculty of Brain Sciences, UCL Queen Square Institute of Neurology; Moorfields Eye Hospital and The National Hospital for Neurology and Neurosurgery, University College London, United Kingdom; Department of Neurology, Amsterdam UMC, Vrije Universiteit Amsterdam, MS Centre and Neuro-ophthalmology Expertise Centre Amsterdam, Amsterdam Neuroscience, Netherlands	Major role in the acquisition of data; study concept or design; and analysis or interpretation of data

## Appendix (continued)

Name	Location	Contribution
<b>Ahmed T. Toosy, MD, PhD, FRCP</b>	Department of Neuroinflammation, Queen Square MS Centre, Faculty of Brain Sciences, UCL Queen Square Institute of Neurology; Moorfields Eye Hospital and The National Hospital for Neurology and Neurosurgery, University College London, United Kingdom	Major role in the acquisition of data; study concept or design; and analysis or interpretation of data
<b>Benjamin Knier, MD</b>	Department of Neurology, Klinikum rechts der Isar, TUM School of Medicine, Technical University of Munich, Germany	Major role in the acquisition of data; study concept or design; and analysis or interpretation of data

## References

- Petzold A, Balcer LJ, Calabresi PA, et al. Retinal layer segmentation in multiple sclerosis: a systematic review and meta-analysis. *Lancet Neurol.* 2017;16(10):797-812. doi:10.1016/S1474-4422(17)30278-8
- Oertel FC, Specovius S, Zimmermann HG, et al. Retinal optical coherence tomography in neuromyelitis optica. *Neurol Neuroimmunol Neuroinflamm.* 2021;8(6):e1068. doi:10.1212/NXI.0000000000001068
- Kansal V, Armstrong JJ, Pintwala R, Hutnik C. Optical coherence tomography for glaucoma diagnosis: an evidence based meta-analysis. *PLoS ONE.* 2018;13(1):e0190621. doi:10.1371/journal.pone.0190621
- Virgili G, Menchini F, Murro V, Peluso E, Rosa F, Casazza G. Optical coherence tomography (OCT) for detection of macular oedema in patients with diabetic retinopathy. *Cochrane Database Syst Rev.* 2011;7:CD008081. doi:10.1002/14651858.CD008081.pub2
- Dziedzic J, Zaleska-Żmijewska A, Szaflik JP, Cudnoch-Jędrzejewska A. Impact of arterial hypertension on the eye: a review of the pathogenesis, diagnostic methods, and treatment of hypertensive retinopathy. *Med Sci Monit.* 2022;28:e935135. doi:10.12659/MSM.935135
- Nolan-Kenney RC, Liu M, Akhand O, et al. Optimal intereye difference thresholds by optical coherence tomography in multiple sclerosis: an international study. *Ann Neurol.* 2019;85(5):618-629. doi:10.1002/ana.25462
- Lambe J, Fitzgerald KC, Murphy OC, et al. Association of spectral-domain OCT with long-term disability worsening in multiple sclerosis. *Neurology.* 2021;96(16):e2058-e2069. doi:10.1212/WNL.00000000000011788
- Wauschkuhn J, Solorza Buenrostro G, Aly L, et al. Retinal ganglion cell loss is associated with future disability worsening in early relapsing-remitting multiple sclerosis. *Eur J Neurol.* 2023;30(4):982-990. doi:10.1111/ene.15681
- Zimmermann HG, Knier B, Oberwahrenbrock T, et al. Association of retinal ganglion cell layer thickness with future disease activity in patients with clinically isolated syndrome. *JAMA Neurol.* 2018;75(9):1071-1079. doi:10.1001/jamaneurol.2018.1011
- Petzold A, Fraser CL, Abegg M, et al. Diagnosis and classification of optic neuritis. *Lancet Neurol.* 2022;21(12):1120-1134. doi:10.1016/S1474-4422(22)00200-9
- Bsteh G, Hege H, Altmann P, et al. Diagnostic performance of adding the optic nerve region assessed by optical coherence tomography to the diagnostic criteria for MS. *Neurology.* 2023;101(8):e784-e793. doi:10.1212/WNL.000000000000207507
- Tewarie P, Balk L, Costello F, et al. The OSCAR-IB consensus criteria for retinal OCT quality assessment. *PLoS ONE.* 2012;7(4):e34823. doi:10.1371/journal.pone.0034823
- Schipping S, Balk LJ, Costello F, et al. Quality control for retinal OCT in multiple sclerosis: validation of the OSCAR-IB criteria. *Mult Scler J.* 2015;21(2):163-170. doi:10.1177/1352458514538110
- Aytulun A, Cruz-Herranz A, Aktas O, et al. APOSTEL 2.0 recommendations for reporting quantitative optical coherence tomography studies. *Neurology.* 2021;97(2):68-79. doi:10.1212/WNL.00000000000012125
- Campbell JP, Zhang M, Hwang TS, et al. Detailed vascular anatomy of the human retina by projection-resolved optical coherence tomography angiography. *Sci Rep.* 2017;7:42201. doi:10.1038/srep42201
- Maesa J-M, Baños-Álvarez E, Rosario-Lozano M-P, Blasco-Amaro J-A. Diagnostic accuracy of optical coherence tomography angiography in the detection of neovascularization in age-related macular degeneration: a meta-analysis. *Acta Ophthalmol.* 2022;100(2):e368-e376. doi:10.1111/aos.14979
- Zhang B, Chou Y, Zhao X, Yang J, Chen Y. Early detection of microvascular impairments with optical coherence tomography angiography in diabetic patients without clinical retinopathy: a meta-analysis. *Am J Ophthalmol.* 2021;222:226-237. doi:10.1016/j.ajo.2020.09.032
- Miguel AIM, Silva AB, Azevedo LF. Diagnostic performance of optical coherence tomography angiography in glaucoma: a systematic review and meta-analysis. *Br J Ophthalmol.* 2019;103(11):1677-1684. doi:10.1136/bjophthalmol-2018-313461

19. Aly L, Noll C, Wicklein R, et al. Dynamics of retinal vessel loss after acute optic neuritis in patients with relapsing multiple sclerosis. *Neurol Neuroimmunol Neuroinflamm.* 2022;9(3). doi:10.1212/NXI.0000000000001159
20. Noll C, Hiltensperger M, Aly L, et al. Association of the retinal vasculature, intrathecal immunity, and disability in multiple sclerosis. *Front Immunol.* 2022;13:997043. doi:10.3389/fimmu.2022.997043
21. Murphy OC, Kalaitzidis G, Vasileiou E, et al. Optical coherence tomography and optical coherence tomography angiography findings after optic neuritis in multiple sclerosis. *Front Neurol.* 2020;11:618879. doi:10.3389/fneur.2020.618879
22. Murphy OC, Kwakyi O, Iftikhar M, et al. Alterations in the retinal vasculature occur in multiple sclerosis and exhibit novel correlations with disability and visual function measures. *Mult Scler J.* 2020;26(7):815-828. doi:10.1177/1352458519845116
23. Lim HB, Kim YW, Kim JM, Jo YJ, Kim JY. The importance of signal strength in quantitative assessment of retinal vessel density using optical coherence tomography angiography. *Sci Rep.* 2018;8(1):12897. doi:10.1038/s41598-018-31321-9
24. Al-Sheikh M, Ghasemi Falavarjani K, Akil H, Sadda SR. Impact of image quality on OCT angiography based quantitative measurements. *Int J Retina Vitreous.* 2017;3:13. doi:10.1186/s40942-017-0068-9
25. Watanabe Y, Takahashi Y, Numazawa H. Graphics processing unit accelerated intensity-based optical coherence tomography angiography using differential frames with real-time motion correction. *J Biomed Opt.* 2014;19(2):21105. doi:10.1117/1.JBO.19.2.021105
26. Fleiss JL. *Statistical Methods for Rates and Proportions*, 3rd ed. Wiley-Interscience; 2003.
27. Landis JR, Koch GG. The measurement of observer agreement for categorical data. *Biometrics.* 1977;33(1):159-174.
28. Mihailovic N, Lauermann JL, Schubert F, et al. Vergleich der Bildqualität zweier unterschiedlicher OCT-Angiografie-Systeme mit Fokus auf Bewegungsartefakten bei gesunden Probanden. *Klin Monbl Augenheilkd.* 2019;236(9):1115-1121. doi:10.1055/a-0838-5880
29. Holmen IC, Konda SM, Pak JW, et al. Prevalence and severity of artifacts in optical coherence tomographic angiograms. *JAMA Ophthalmol.* 2020;138(2):119-126. doi:10.1001/jamaophthalmol.2019.4971
30. Enders C, Lang GE, Dreyhaupt J, Loidl M, Lang GK, Werner JU. Quantity and quality of image artifacts in optical coherence tomography angiography. *PLoS ONE.* 2019;14(1):e0210505. doi:10.1371/journal.pone.0210505
31. Lujan BJ, Calhoun CT, Glassman AR, et al. Optical coherence tomography angiography quality across three multicenter clinical studies of diabetic retinopathy. *Transl Vis Sci Technol.* 2021;10(3):2. doi:10.1167/tvst.10.3.2
32. Pohlmann D, Berlin M, Reidl F, et al. Longitudinal comparison of constant artifacts in optical coherence tomography angiography in patients with posterior uveitis compared to healthy subjects. *J Clin Med.* 2022;11(18):5376. doi:10.3390/jcm11185376
33. Reich M, Boehringer D, Rothaus K, et al. Swept-source optical coherence tomography angiography alleviates shadowing artifacts caused by subretinal fluid. *Int Ophthalmol.* 2020;40(8):2007-2016. doi:10.1007/s10792-020-01376-7
34. Lee JJ, Lee JE, Sadda SR, Park SW, Byon I. Impact of signal strength on quantitative retinal and choriocapillaris flow measurement from optical coherence tomography angiography. *Sci Rep.* 2022;12(1):4692. doi:10.1038/s41598-022-08781-1
35. Lim HB, Kim YW, Nam KY, Ryu CK, Jo YJ, Kim JY. Signal strength as an important factor in the analysis of peripapillary microvascular density using optical coherence tomography angiography. *Sci Rep.* 2019;9(1):16299. doi:10.1038/s41598-019-52818-x
36. Feucht N, Maier M, Lepennetier G, et al. Optical coherence tomography angiography indicates associations of the retinal vascular network and disease activity in multiple sclerosis. *Mult Scler J.* 2019;25(2):224-234. doi:10.1177/1352458517750009
37. Ghasemi Falavarjani K, Habibi A, Anvari P, et al. Effect of segmentation error correction on optical coherence tomography angiography measurements in healthy subjects and diabetic macular oedema. *Br J Ophthalmol.* 2020;104(2):162-166. doi:10.1136/bjophthalmol-2019-314018
38. Bontzos G, Kabanarou SA, Garnavou-Xirou C, et al. Segmentation errors and motion artifacts in OCT-A associated with epiretinal membranes. *Can J Ophthalmol.* 2020;55(4):293-300. doi:10.1016/j.jjco.2019.12.007
39. Zhang Y, Yang L, Gao Y, et al. Choroid and choriocapillaris changes in early-stage Parkinson's disease: a swept-source optical coherence tomography angiography-based cross-sectional study. *Alzheimer's Res Ther.* 2022;14(1):116. doi:10.1186/s13195-022-01054-z
40. Aly L, Strauß E-M, Feucht N, et al. Optical coherence tomography angiography indicates subclinical retinal disease in neuromyelitis optica spectrum disorders. *Mult Scler.* 2022;28(4):522-531. doi:10.1177/13524585211028831
41. Lauermann JL, Treder M, Heiduschka P, Clemens CR, Eter N, Alten F. Impact of eye-tracking technology on OCT-angiography imaging quality in age-related macular degeneration. *Graefes Arch Clin Exp Ophthalmol.* 2017;255(8):1535-1542. doi:10.1007/s00417-017-3684-z
42. Lauermann JL, Woetzel AK, Treder M, et al. Prevalences of segmentation errors and motion artifacts in OCT-angiography differ among retinal diseases. *Graefes Arch Clin Exp Ophthalmol.* 2018;256(10):1807-1816. doi:10.1007/s00417-018-4053-2
43. Woetzel AK, Lauermann JL, Kreitz K, et al. Optical coherence tomography angiography image quality assessment at varying retinal expertise levels. *J Curr Ophthalmol.* 2019;31(2):161-167. doi:10.1016/j.joco.2018.12.002
44. Cui Y, Zhu Y, Wang JC, et al. Imaging artifacts and segmentation errors with wide-field swept-source optical coherence tomography angiography in diabetic retinopathy. *Transl Vis Sci Technol.* 2019;8(6):18. doi:10.1167/tvst.8.6.18
45. Mohammadi S, Gouravani M, Salehi MA, et al. Optical coherence tomography angiography measurements in multiple sclerosis: a systematic review and meta-analysis. *J Neuroinflammation.* 2023;20(1):85. doi:10.1186/s12974-023-02763-4

# Neurology<sup>®</sup> Neuroimmunology & Neuroinflammation

## The OSCAR-MP Consensus Criteria for Quality Assessment of Retinal Optical Coherence Tomography Angiography

Rebecca Wicklein, Charmaine Yam, Christina Noll, et al.  
*Neurol Neuroimmunol Neuroinflamm* 2023;10;  
DOI 10.1212/NXI.0000000000200169

This information is current as of October 9, 2023

<b>Updated Information &amp; Services</b>	including high resolution figures, can be found at: <a href="http://nn.neurology.org/content/10/6/e200169.full.html">http://nn.neurology.org/content/10/6/e200169.full.html</a>
<b>References</b>	This article cites 44 articles, 7 of which you can access for free at: <a href="http://nn.neurology.org/content/10/6/e200169.full.html#ref-list-1">http://nn.neurology.org/content/10/6/e200169.full.html#ref-list-1</a>
<b>Subspecialty Collections</b>	This article, along with others on similar topics, appears in the following collection(s): <b>All Imaging</b> <a href="http://nn.neurology.org/cgi/collection/all_imaging">http://nn.neurology.org/cgi/collection/all_imaging</a> <b>Multiple sclerosis</b> <a href="http://nn.neurology.org/cgi/collection/multiple_sclerosis">http://nn.neurology.org/cgi/collection/multiple_sclerosis</a> <b>Retina</b> <a href="http://nn.neurology.org/cgi/collection/retina">http://nn.neurology.org/cgi/collection/retina</a>
<b>Permissions &amp; Licensing</b>	Information about reproducing this article in parts (figures, tables) or in its entirety can be found online at: <a href="http://nn.neurology.org/misc/about.xhtml#permissions">http://nn.neurology.org/misc/about.xhtml#permissions</a>
<b>Reprints</b>	Information about ordering reprints can be found online: <a href="http://nn.neurology.org/misc/addir.xhtml#reprintsus">http://nn.neurology.org/misc/addir.xhtml#reprintsus</a>

*Neurol Neuroimmunol Neuroinflamm* is an official journal of the American Academy of Neurology. Published since April 2014, it is an open-access, online-only, continuous publication journal. Copyright Copyright © 2023 The Author(s). Published by Wolters Kluwer Health, Inc. on behalf of the American Academy of Neurology.. All rights reserved. Online ISSN: 2332-7812.

