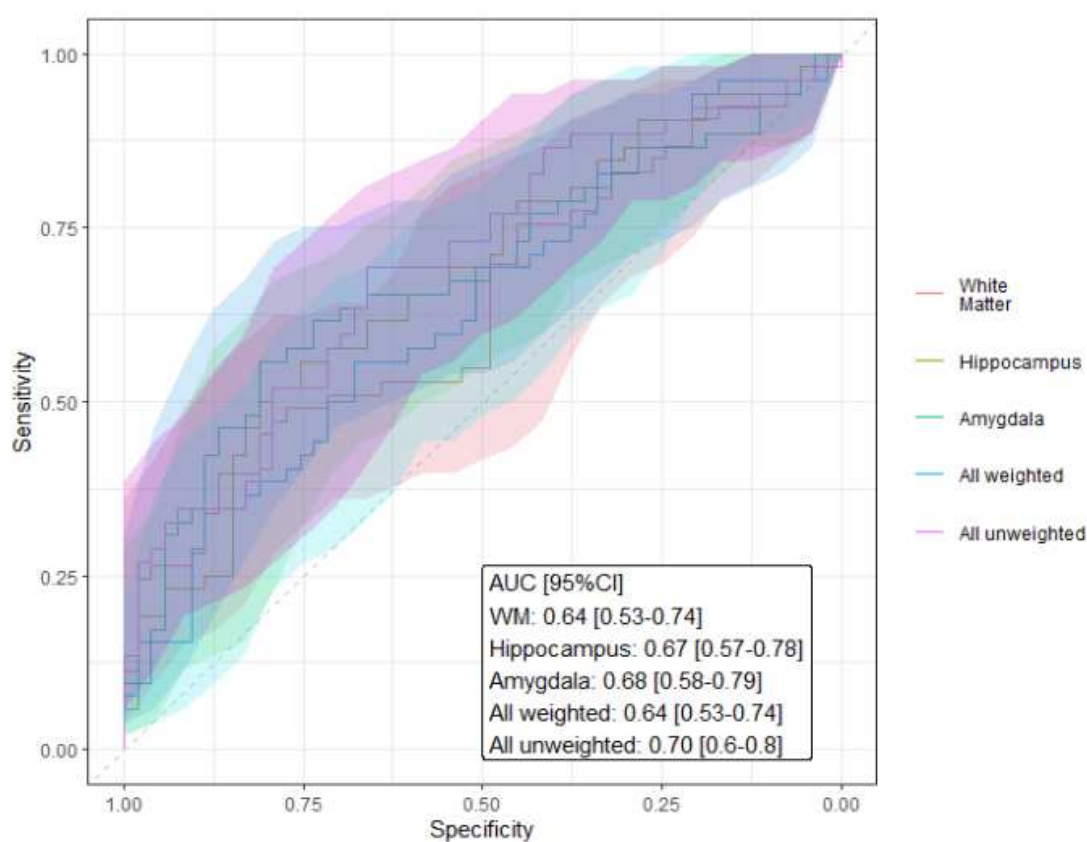


Supplementary Materials

The T1-weighted/T2-weighted ratio as a biomarker of anti-NMDA receptor encephalitis

Tim J. Hartung, Graham Cooper, Valentin Jünger, Darko Komnenić, Lara Ryan, Josephine Heine, Claudia Chien, Friedemann Paul, Harald Prüss, Carsten Finke



eFigure 1. Receiver operating curves for recognition of NMDAR encephalitis patients by T1w/T2w ratio in white matter (WM), hippocampus, amygdala and thalamus. Combined measure weighting based on logistic regression model. Shaded area represents 95% CI; AUC, area under the curve; CI, confidence interval.

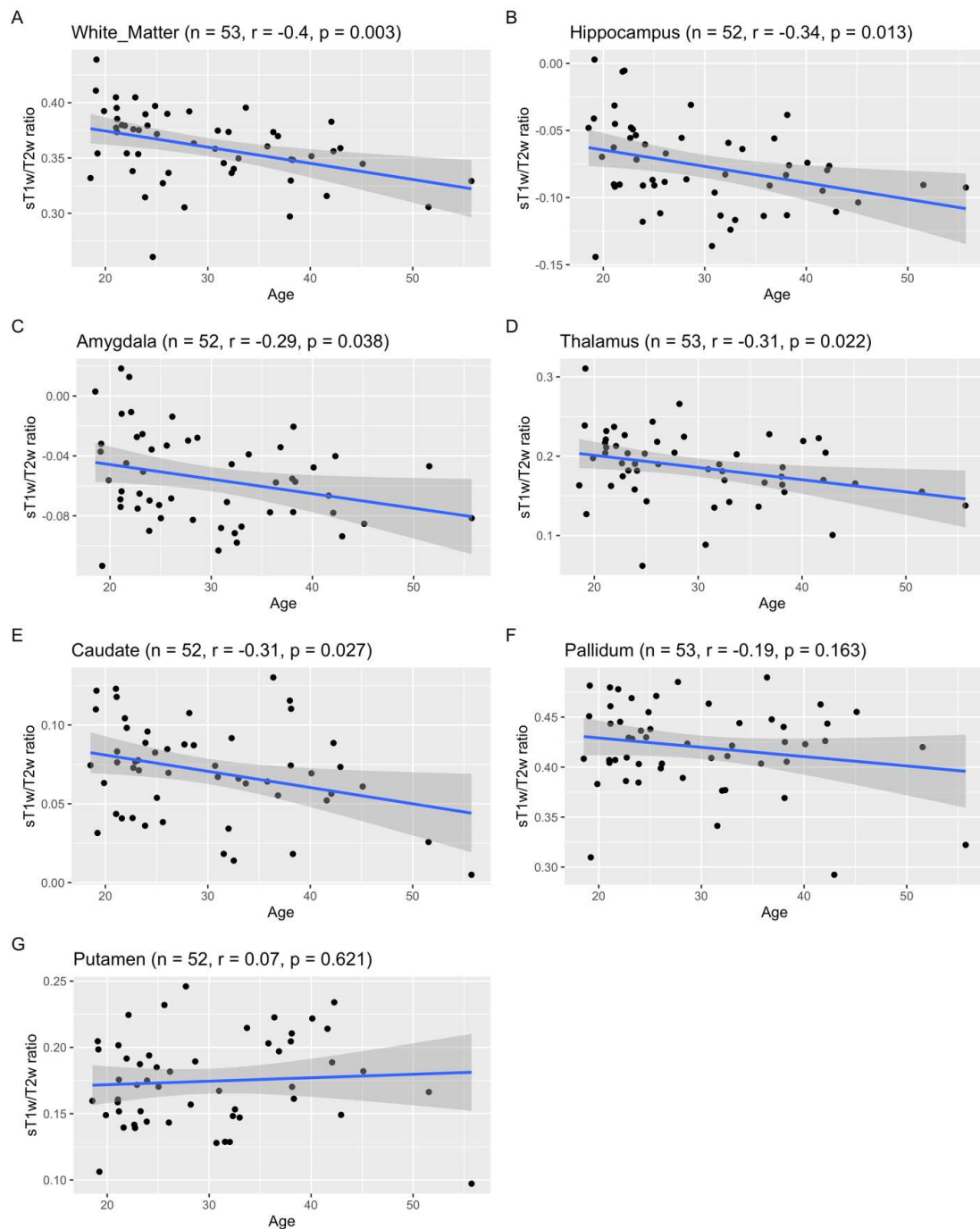


Figure 2. Association between age and T1w/T2w ratio in white matter (A) and deep gray matter structures (B-G); r, Pearson correlation coefficient.

eTable 1. Correlations between cognitive tests and T1w/T2w ratio in normal appearing white matter (NAWM). **Abbreviations:** AVLT auditory verbal learning test, FDR false detection rate correction, ROCF Rey-Osterrieth complex figure, TAP test of attentional performance.

Correlation	r	p	p(FDR)
Digit span forward x NAWM	-0.20	0.16	0.26
AVLT delayed recall x NAWM	0.39	0.01 **	0.03 *
ROCF delayed recall x NAWM	0.23	0.11	0.26
TAP tonic alertness x NAWM	-0.05	0.74	0.74
TAP go/no-go x NAWM	0.08	0.59	0.74

eTable 2. Correlations between cognitive tests and T1w/T2w ratio in deep gray matter structures with significant group differences. **Abbreviations:** AVLT auditory verbal learning test, FDR false detection rate correction, ROCF Rey-Osterrieth complex figure, TAP test of attentional performance.

Correlation	r	p	p(FDR)
Digit span forward x hippocampus	-0.16	0.27	0.52
Digit span forward x amygdala	-0.08	0.57	0.78
Digit span forward x thalamus	-0.37	0.01 **	0.10
AVLT delayed recall x hippocampus	0.19	0.19	0.52
AVLT delayed recall x amygdala	0.19	0.19	0.52
AVLT delayed recall x thalamus	0.15	0.31	0.52
ROCF delayed recall x hippocampus	0.13	0.37	0.56
ROCF delayed recall x amygdala	0.15	0.29	0.52
ROCF delayed recall x thalamus	0.02	0.90	0.96
TAP tonic alertness x hippocampus	-0.01	0.96	0.96
TAP tonic alertness x amygdala	0.04	0.78	0.90
TAP tonic alertness x thalamus	-0.06	0.66	0.82
TAP go/no-go x hippocampus	0.22	0.12	0.52
TAP go/no-go x amygdala	0.23	0.12	0.52
TAP go/no-go x thalamus	0.18	0.21	0.52

eTable 3. Differences in white matter T1T2 ratio by symptom during the acute stage.

Symptom	Hedges g (95% CI)	p	p (FDR)
Psychiatric	-1.52 (-2.55, -0.89)	0.026	0.123
Seizures	-0.31 (-0.89, -0.39)	0.638	0.638
Movement	0.14 (-0.39, -0.84)	0.421	0.638
Autonomic	-0.28 (-0.84, -1.28)	0.596	0.638
Cognitive	-0.37 (-1.28, -0.73)	0.318	0.638

eTable 4. Conventional MRI abnormalities in acute stage and study MRI.
Abbreviations: WM white matter.

Patient	Acute stage MRI	Study MRI
Patient 01	normal	normal
Patient 02	normal	normal
Patient 03	normal	single WM lesion in left parietal lobe
Patient 04	normal	normal
Patient 05	normal	normal
Patient 06	meningeal contrast enhancement, several small non-enhancing deep WM lesions	single WM lesion in left frontal lobe
Patient 07	several small WM lesions in the frontal lobes	several small WM lesions in the frontal lobes
Patient 08	normal	normal
Patient 09	normal	normal
Patient 10	meningeal contrast enhancement	single WM lesion in left frontal lobe
Patient 11	normal	normal
Patient 12	single WM lesion in left frontal lobe	single WM lesion in left frontal lobe
Patient 13	T2/FLAIR hyperintense lesion left medial frontal lobe, no contrast enhancement	normal
Patient 14	normal	normal
Patient 15	single WM lesion left frontal lobe	several small WM lesions in frontal, parietal and temporal lobes
Patient 16	normal	normal
Patient 17	normal	normal
Patient 18	normal	normal
Patient 19	normal	normal
Patient 20	normal	normal
Patient 21	single WM lesion left frontal lobe	normal

Patient 22	slightly enlarged lateral ventricles	normal
Patient 23	small hyperintense lesion in left precentral gyrus with diffusion restriction	normal
Patient 24	isolated small WM lesions	several small WM lesions in frontal, parietal and temporal lobes
Patient 25	normal	normal
Patient 26	normal	normal
Patient 27	T2/FLAIR hyperintense cortical lesion, temporo-occipital left	normal
Patient 28	subarachnoid T2/FLAIR hyperintensity	normal
Patient 29	normal	normal
Patient 30	cerebral vein thrombosis right	several small WM lesions
Patient 31	normal	normal
Patient 32	T2/FLAIR hyperintense WM lesion temporoparietal	normal
Patient 33	normal	normal
Patient 34	normal	normal
Patient 35	normal	normal
Patient 36	several small WM lesions in frontal and parietal lobes	several small WM lesions in frontal lobes
Patient 37	roundish T2 signal elevations in the cerebellar peduncles, band-shaped cortical T2 enhancement in the paramedian right frontal gyrus, extensive T2-lesions in dorsal temporal lobe and occipital, parietal, and frontal WM	normal
Patient 38	several WM lesions in frontal and temporal lobes with contrast enhancement	several small WM lesions in frontal and temporal lobes
Patient 39	normal	normal
Patient 40	normal	normal
Patient 41	several small deep and frontal WM lesions	several small deep and frontal WM lesions
Patient 42	diffuse WM lesions	single WM lesion in left frontal lobe

Patient 43	normal	normal
Patient 44	normal	normal
Patient 45	normal	normal
Patient 46	normal	normal
Patient 47	normal	normal
Patient 48	several small WM lesions	several small WM lesions
Patient 49	normal	normal
Patient 50	T2/FLAIR signal elevation in temporo-occipital WM	normal
Patient 51	FLAIR signal elevation in temporal sulci left with contrast enhancement	normal
Patient 52	single WM lesion frontoparietal right	single WM lesion frontoparietal right
Patient 53	single WM lesion	single WM lesion in left medial temporal lobe