

## Case report



# Homozygous nonsense mutation of *WNT10B* gene in a Moroccan family with split-hand foot malformation identified by exome sequencing: a case report

Siham Chafai Elalaoui, Nawfal Fejjal, Yun Li, Holger Thiele, Janine Altmüller, Soukaina Guaoua, Peter Nürnberg, Bernd Wollnik, Abdelaziz Sefiani, Ilham Ratbi

**Corresponding author:** Siham Chafai Elalaoui, Département de Génétique Médicale, Institut National d'Hygiène, Rabat, Maroc. [sihamgen@yahoo.fr](mailto:sihamgen@yahoo.fr)

**Received:** 21 Sep 2020 - **Accepted:** 28 Apr 2021 - **Published:** 07 May 2021

**Keywords:** Homozygous mutation, WTN10B gene, split-hand foot malformation, case report

**Copyright:** Siham Chafai Elalaoui et al. Pan African Medical Journal (ISSN: 1937-8688). This is an Open Access article distributed under the terms of the Creative Commons Attribution International 4.0 License (<https://creativecommons.org/licenses/by/4.0/>), which permits unrestricted use, distribution, and reproduction in any medium, provided the original work is properly cited.

**Cite this article:** Siham Chafai Elalaoui et al. Homozygous nonsense mutation of *WNT10B* gene in a Moroccan family with split-hand foot malformation identified by exome sequencing: a case report. Pan African Medical Journal. 2021;39(21). 10.11604/pamj.2021.39.21.26176

**Available online at:** <https://www.panafrican-med-journal.com/content/article/39/21/full>

## Homozygous nonsense mutation of *WNT10B* gene in a Moroccan family with split-hand foot malformation identified by exome sequencing: a case report

Siham Chafai Elalaoui<sup>1,2,&</sup>, Nawfal Fejjal<sup>3</sup>, Yun Li<sup>4,5,6</sup>, Holger Thiele<sup>7</sup>, Janine Altmüller<sup>7</sup>, Soukaina Guaoua<sup>1</sup>, Peter Nürnberg<sup>7</sup>, Bernd Wollnik<sup>4,5,6</sup>, Abdelaziz Sefiani<sup>1,2</sup>, Ilham Ratbi<sup>1,2</sup>

<sup>1</sup>Génomique et Epidémiologie Moléculaire des Maladies Génétiques (G2MG), Centre GENOPATH,

Faculté de Médecine et de Pharmacie, Mohammed V University in Rabat, Rabat, Maroc, <sup>2</sup>Département de Génétique Médicale, Institut National d'Hygiène, Rabat, Maroc, <sup>3</sup>Service de Chirurgie Plastique Pédiatrique, Hôpital des Enfants, Centre Hospitalier Universitaire Ibn Sina, Faculté de Médecine et de Pharmacie, Université Mohammed V, Rabat, Maroc, <sup>4</sup>Center for Molecular Medicine Cologne (CMMC), University of Cologne, Cologne, Germany, <sup>5</sup>Institute of Human Genetics, University Hospital Cologne, University of Cologne, Cologne,

Germany, <sup>6</sup>Cologne Excellence Cluster on Cellular Stress Responses in Aging-Associated Diseases (CECAD), University of Cologne, Cologne, Germany, <sup>7</sup>Cologne Center for Genomics, University of Cologne, Cologne, Germany

#### **&Corresponding author**

Siham Chafai Elalaoui, Département de Génétique Médicale, Institut National d'Hygiène, Rabat, Maroc

## **Abstract**

*Split-hand foot malformation (SHFM) is a clinically heterogeneous congenital limb defect affecting predominantly the central rays of hands and/or feet. The clinical expression varies in severity between patients as well between the limbs in the same individual. SHFM might be non-syndromic with limb-confined manifestations or syndromic with extra-limb manifestations. Isolated SHFM is a rare condition with an incidence of about 1 per 18,000 live born infants and accounts for 8-17 % of all limb malformations. To date, many chromosomal loci and genes have been described as associated with isolated SHFM, i.e., SHFM1 to 6. SHFM6 is one of the rarest forms of SHFM, and is caused by mutations in WNT10B gene. Less than ten pathogenic variants have been described. We have investigated a large consanguineous Moroccan family with three affected members showing feet malformations with or without split hand malformation phenotypes. Using an exome sequencing approach, we identified a homozygous nonsense variant p.Arg115\* of WNT10B gene retaining thereby the diagnosis of SHFM6. This homozygous nonsense mutation identified by exome sequencing in a large family of split hand foot malformation highlights the importance of exome sequencing in genetically heterogeneous entities.*

## **Introduction**

Split-hand foot malformation (SHFM) is a clinically and genetically heterogeneous condition

characterized by congenital limb defect affecting predominantly the central rays of hands and/or feet [1]. The clinical expression varies in severity between patients as well between the limbs in the same individual [2,3]. SHFM might be non-syndromic with limb-confined manifestations or syndromic with extra-limb manifestations [4]. Isolated SHFM is a rare condition with an incidence of about 1 per 18,000 live born infants and accounts for 8-17 % of all limb malformations [5]. To date, seven chromosomal loci associated with isolated SHFM have been described, i.e., SHFM1 to 6. Most of the known SHFM loci are associated with chromosomal rearrangements that involve small deletions or duplications of the human genome. In addition, five genes, i.e., TP63 (tumor protein p63, MIM 603273), WNT10B (awingless-type MMTV integration site family, member 10B, MIM 601906), DLX5 (distal-less homeobox5, MIM 600028), ZAK (leucine zipper- and sterile alpha motif-containing kinase, MIM 609479), and CDH3 (cadherin3, MIM 114021), are known to carry point mutations in patients affected by SHFM [1]. The autosomal dominant mode of inheritance is typical for SHFM1 (DLX5 gene on 7q21), SHFM3 on 10q24, SHFM4 (TP63 gene on 3q28) and SHFM5 on 2q31 [6-12]. Two autosomal recessive forms have been reported, i.e., SHFM1D associated with deafness, due to DLX5 mutations and SHFM6 due to WNT10B mutations [9,12,13]. In addition, SHFM2 has been assigned to Xq26 by linkage analyses in a large Pakistani kindred [4]. In this study, using an exome sequencing approach, we identified a homozygous nonsense WNT10B mutation, in a large consanguineous Moroccan family with three affected members showing feet and split hand malformations malformation phenotypes, confirming the diagnosis of SHFM6.

## **Patient and observation**

**Clinical presentation:** the propositus II: 6, a twelve years-old female, was referred to our institute for a medical genetic consultation with a chief complaint of malformations. She was the sixth liveborn child of a healthy consanguineous couple from an

isolated village of the South of Morocco. Her parents reported normal psychomotor development. On clinical examination, she had very mild facial dysmorphism including flat nasal bridge, down slanting palpebral fissures, short prominent philtrum, high arched palate and crowded teeth. She showed syndactylies and clefts on both hands and feet. On the right hand, she had cleft hand deformity, syndactyly of the thumb and second finger, absence of the third finger, and a deformity of the proximal phalanx of the 4<sup>th</sup> finger. On the left hand, she had a radial deviation of the thumb and second finger, partial cutaneous syndactyly of the thumb and second finger, cutaneous syndactyly of the third and fourth fingers, and an ulnar deviation of the third, fourth and fifth fingers (Figure 1A). On the right foot, she had cleft foot, with a broad hallux and apparently absence of the second toe, cutaneous syndactyly of the fourth and fifth toes, and absence of the third toe. There was also a cutaneous syndactyly of the first and second metatarses, on one part and on the other part, cutaneous syndactyly of the third, fourth and fifth metatarses. On the left foot, she had a cleft foot, with a very broad hallux, concordant with a syndactyly of the hallux and the second toe, and cutaneous syndactyly of the third and fourth toes (Figure 1B). She did not have other somatic abnormalities.

Radiography showed on right hand, a cleft hand deformity, with deformity of the second and third phalanges of the second finger, absence of the third finger, with ulnar deviation of the fourth and fifth fingers. On left hand, radiography showed radial deviation of the thumb and the second finger (Figure 1C). Radiography of the right foot showed osseous syndactyly of the hallux and the second toe, absence of the third toe. Radiography of the left foot showed fusion of the second phalanges of the hallux and second toe, absence of the second phalanx of the third toe (Figure 1D). Radiography of upper and lower limbs was normal. Cardiac, abdominal and pelvic ultrasonographies were normal. Two other older affected siblings, a female of 25 and a male of 18 had isolated cutaneous syndactyly of toes without involvement of hands or

other malformations. Parents did not show any hand or foot malformation, and their teeth examinations were normal.

**Genetic analysis:** all patients or their legal representatives gave written informed consent to the study, which was performed in accordance with the Declaration of Helsinki protocols and approved by the local institutional review boards. Deoxyribonucleic acid (DNA) was isolated from peripheral blood for all patients using standard techniques [14]. Complete DNA Sanger sequence analysis of the entire coding region and flanking introns of the LRP4 gene was performed in the proband DNA sample on an ABI3730 DNA sequence (Applied Biosystems, Foster City, CA, USA) as reported previously [15]. Whole Exome Sequencing (WES) was undertaken for individuals I: 1, I: 2, II: 6 (Figure 2A). DNA enrichment for WES was achieved using Nimble GenSeqCap EZ Human Exome Library v2.0. Paired-end sequencing (100bp) was run on an IlluminaHiSEQ2000. Sanger sequencing of all 38 exons of LRP4 gene did not identify any putative mutation. In data analysis of WES, when we selected biallelic variants or previously reported pathogenic non-synonymous, frameshift, nonsense or splice site variants consistent with recessive inheritance that co-segregated with the disease phenotype, we identified putative causing variant in *WNT10B* (MIM 601906; NM\_003394.3). It was a homozygous nonsense variant R115\* in exon 4. The resultant transcript was assumed to lead to the expression of a truncated protein. It was confirmed by Sanger sequencing, predicted to be damaging and segregated with the disease phenotype, such that all affected individuals were homozygous, whereas unaffected parents were heterozygous and unaffected sibling II : 3 was homozygous for the wild type (Figure 2A, Figure 2B).

## Discussion

Split-hand/split-foot malformation (SHFM), representing variable degree of median clefts of hands and feet, is a genetically heterogeneous group of limb malformations with seven loci mapped on different human chromosomes.

However, only 3 genes (*TP63*, *WNT10B*, *DLX5*) for the seven loci have been identified [1]. Phenotypic variability has been reported not only among families but also among affected members within the same family. In few cases, even within the same individual one extremity was found more affected than the other [1]. SHFM6 type 6 is inherited as an autosomal recessive manner. This entity is due to mutations in *WNT10B* gene [13]. Twelve affected members from a large Turkish family exhibiting autosomal recessive inheritance for SHFM were firstly clinically described [16]. All patients had central feet reductions with or without hand involvement, except one individual who had just unilateral hand syndactyly with no foot involvement. Six years later, this family was enrolled in a homozygosity mapping study. It leads to the identification of a novel SHFM locus at 12q13.11-q13 and by subsequent candidate gene approach a homozygous missense *WNT10B* mutation (p.Arg332Trp) [13].

This homozygous mutation was interestingly also found in one unaffected individual from the same family, whereas the patient with atypical SHFM was not carried. To explain the observed phenotypes in this family, authors assumed that maybe a *WNT10B* mutation is necessary, but not sufficient to produce SHFM. The second reported case was a sporadic Swiss patient with a homozygous 4-bp duplication resulting in a premature termination codon in *WNT10B* gene. Nine heterozygous relatives showed no sign of SHFM [17]. This case supported that sporadic SHFM is not always a dominant trait and that testing for mutations in *WNT10B* should be also considered for these patients. In 2012, a third novel homozygous c.986C>G, p.Thr329Arg mutation in *WNT10B* gene, was found in a large consanguineous Pakistani family with autosomal recessive SHFM phenotype involving hands and feet, and appearing in two generations [18]. Recently, three other consanguineous Pakistani families segregating autosomal recessive SHFM, with phenotypic variability grading from mild preaxial to post-axial involvement as simple syndactyly to severe central clefting of the autopods were reported. Genotyping microsatellite

markers and mutation screening of *WNT10B* by Sanger DNA sequencing identified a homozygous 4-bp deletion (c.1165\_1168delAAGT) in one family and a homozygous 7-bp duplication (c.300\_306dupAGGGCGG) in the two others [19].

To the best of our knowledge, the Moroccan family reported here is therefore the seventh case in the literature with SHFM6 (Figure 2C). We were firstly clinically oriented to a Cenani-Lens syndrome because of the slight facial dysmorphism of the proband and the autosomal recessive segregation associated to complex syndactyly of hands and feet, even if she presented no malformations of the forearm bones. The other affected siblings did exhibit neither relevant dysmorphism nor anomalies of the forearm bones. Sanger sequencing of *LRP4* gene did not identify any variant. Lastly, exome sequencing was performed because of the higher clinical and genetic heterogeneity of this type of limb disorders and leads to define the genetic basis in this family. The identified homozygous *WNT10B* mutation p. R115\* was previously reported in heterozygous state in a patient with Split hand foot [20].

## Conclusion

In conclusion, we report on the first clinical and molecular description of a Moroccan family with autosomal recessive SHFM. This diagnosis allowed us to provide an appropriate course of management to patients, and offer genetic counseling to the family.

## Competing interests

The authors declare no competing interests.

## Authors' contributions

Siham Chafai Elalaoui and Ilham Ratbi participated in the clinical diagnosis and drafted the manuscript; Yun Li carried out the molecular genetic studies; Nawfal Fejjal participated in the clinical diagnosis and monitoring of the patients. Holger Thiele,



Janine Altmüller, Soukaina Guaoua and Peter Nürnberg carried out the molecular genetic studies. Bernd Wollnik and Abdelaziz Sefiani participated in the design of the study and helped to draft the manuscript. All the authors read and approved the final version of the manuscript.

## Figures

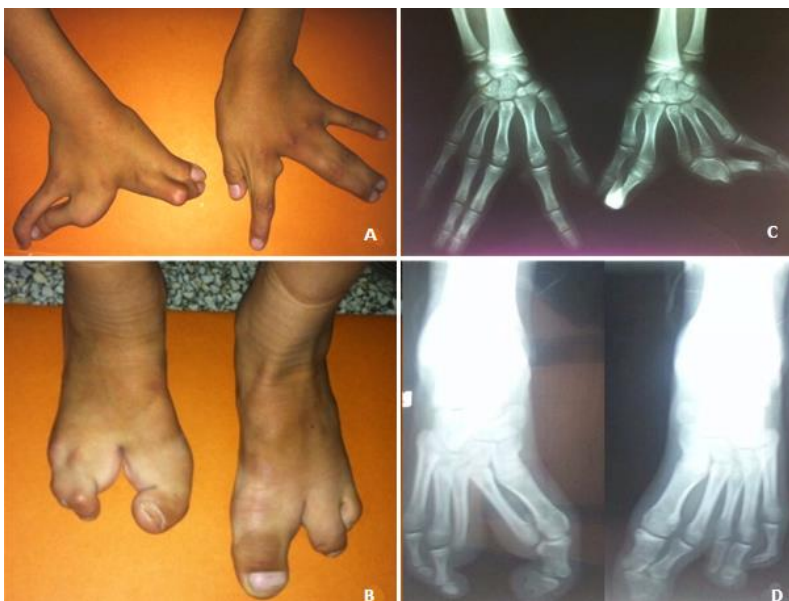**Figure 1:** clinical (A, B) and radiological (C, D) features of SHFM phenotypes observed in patient II: 6

**Figure 2:** A) pedigrees of the studied family, affected individuals are shaded, the proband is indicated by an arrow; investigated members by WES and Sanger sequencing are with an asterisk; B) electropherograms of identified homozygous *WNT10B* mutation; two patients (II: 4 and II:6) present homozygous R115 and both parents are heterozygotes (I: 1 and I: 2); one health brother (II: 3) shows homozygous wild-type; C) schematic view of the *WNT10B* gene structure, protein domains, and localization of identified *WNT10B* mutations; the mutations reported were indicated with green frame and the mutation identified in this study was indicated with red frame

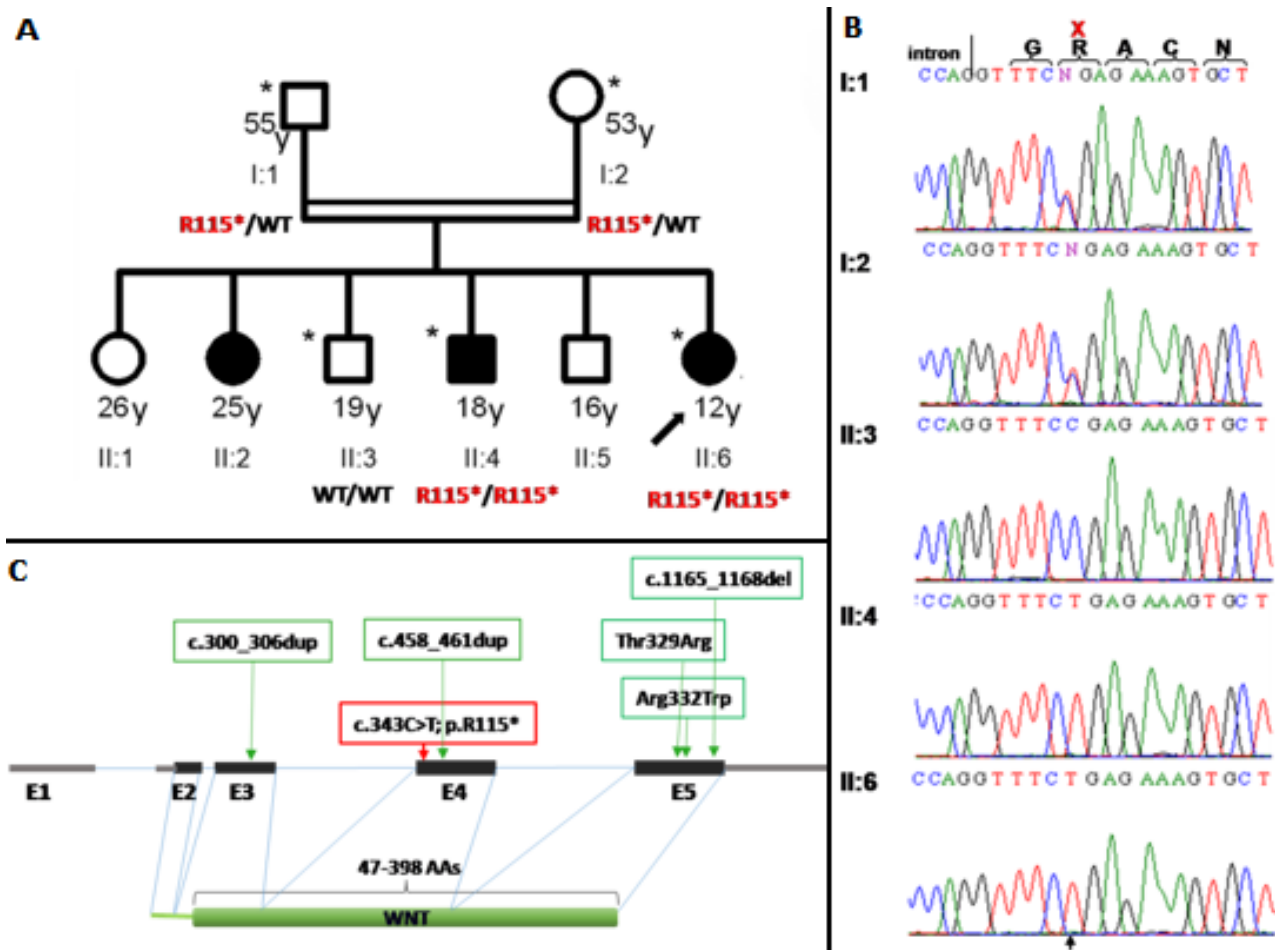
## References

1. Sowinska-Seidler A, Sochav M, Jamsheer A. Split-hand/foot malformation - molecular cause and implications in genetic counseling. *J Appl Genet.* 2014;55(1): 105-115. [PubMed](#) | [Google Scholar](#)
2. Duijf PH, van Bokhoven H, Brunner HG. Pathogenesis of split-hand/split-foot malformation. *Hum Mol Genet.* 2003;12(1): 51-60. [PubMed](#) | [Google Scholar](#)
3. Elliott AM, Evans JA. Genotype-phenotype correlations in mapped split hand foot malformation (SHFM) patients. *Am J Med Genet A.* 2006;140(13): 1419-1427. [PubMed](#) | [Google Scholar](#)
4. Gurrieri F, Everman DB. Clinical, genetic, and molecular aspects of split-hand/foot malformation: an update. *Am J Med Genet A.* 2013;161A(11): 2860-2872. [PubMed](#) | [Google Scholar](#)
5. Czeizel AE, Vitez M, Kodaj I, Lenz W. An epidemiological study of isolated split hand/foot in Hungary: 1975-1984. *J Med Genet.* 1993;30(7): 593-596. [PubMed](#) | [Google Scholar](#)
6. Scherer SW, Poorkaj P, Massa H Soder S, Allen T, Nunes M, Geshuri D *et al.* Physical mapping of the split hand/split foot locus on chromosome 7 and implication in syndromic ectrodactyly. *Hum Mol Genet.* 1994;3(8): 1345-1354. [PubMed](#) | [Google Scholar](#)
7. Gurrieri F, Prinos P, Tackels D, Kilpatrick MW, Allanson J, Genuardi M *et al.* A split hand-split foot (SHFM3) gene is located at 10q24>25. *Am J Med Genet.* 1996;62(4): 427-436. [PubMed](#) | [Google Scholar](#)
8. Nunes ME, Schutt G, Kapur RP, Luthardt F, Kukolich M, Byers P *et al.* A second autosomal split hand/split foot locus maps to chromosome 10q24-q25. *Hum Mol Genet.* 1995;4(11): 2165-2170. [PubMed](#) | [Google Scholar](#)
9. Lanakiev P, Kilpatrick MW, Toudjarska I, Basel D, Beighton P, Tsipouras P. Split-hand/split-foot malformation is caused by mutations in the p63 gene on 3q27. *Am J Hum Genet.* 2000;67(1): 59-66. [PubMed](#) | [Google Scholar](#)
10. Boles RG, Pober BR, Gibson LH, Willis CR, McGrath J, Roberts DJ *et al.* Deletion of chromosome 2q24-q31 causes characteristic digital anomalies: case report and review. *Am J Med Genet.* 1995; 55(2): 155-160. [PubMed](#) | [Google Scholar](#)
11. Al Ghamdi MA, Al-Qattan MM, Hadadi A , Alabdulrahman A, Almuzzaini B, Alatwi N *et al.* A classification system for split-hand/ foot malformation (SHFM): a proposal based on 3 pedigrees with *WNT10B* Mutations. *Eur J Med Genet.* 2020;63(3): 103738. [PubMed](#) | [Google Scholar](#)

12. Brunelle P, Jourdain AS, Escande F, Martinovic J, Dupont J, Busa T *et al.* *WNT10B* variants in split hand/foot malformation: report of three novel families and review of the literature. *Am J Med Genet A.* 2019;179(7): 1351-1356. **PubMed** | **Google Scholar**
13. Ugur SA, Tolun A. Homozygous *WNT10B* mutation and complex inheritance in Split-Hand/Foot Malformation. *Hum Mol Genet.* 2008;17(17): 2644-2653. **PubMed** | **Google Scholar**
14. Miller SA, Dykes DD, Polesky HF. A simple salting out procedure for extracting DNA from human nucleated cells. *Nucleic Acids Res.* 1988; 16(3): 1215. **PubMed** | **Google Scholar**
15. Li Y, Pawlik B, Elcioglu N, Aglan M, Kayserili H, Yigit G *et al.* LRP4 mutations alter Wnt/beta-catenin signaling and cause limb and kidney malformations in Cenani-Lenz syndrome. *Am J Hum Genet.* 2010;86(5): 696-706. **PubMed** | **Google Scholar**
16. Gul D, Oktenli C. Evidence for autosomal recessive inheritance of split hand/split foot malformation: a report of nine cases. *Clin Dymorphol.* 2002; 11(3): 183-186. **PubMed** | **Google Scholar**
17. Blattner A, Huber AR, Rothlisberger B. Homozygous nonsense mutation in *WNT10B* and sporadic split-hand/foot malformation (SHFM) with autosomal recessive inheritance. *Am J Med Genet A.* 2010; 152A(8): 2053-2056. **PubMed** | **Google Scholar**
18. Khan S, Basit S, Zimri FK, Ali N, Ali G, Ansar M *et al.* A novel homozygous missense mutation in *WNT10B* in familial split-hand/foot malformation. *Clin Genet.* 2012; 82(1): 48-55. **PubMed** | **Google Scholar**
19. Aziz A, Irfanullah, Khan S, Zimri FK, Muhammad N, Rashid S *et al.* Novel homozygous mutations in the *WNT10B* gene underlying autosomal recessive split hand/foot malformation in three consanguineous families. *Gene.* 2014; 534(2): 265-271. **PubMed** | **Google Scholar**
20. Jourdain AS, Petit F, Odou MF, Balduyck M, Brunelle P, Dufour W *et al.* Multiplex targeted high-throughput sequencing in a series of 352 patients with congenital limb malformations. *Hum Mutat.* 2020;41(1): 222-239. **PubMed** | **Google Scholar**



**Figure 1:** clinical (A, B) and radiological (C, D) features of SHFM phenotypes observed in patient II: 6



**Figure 2:** A) pedigrees of the studied family, affected individuals are shaded, the proband is indicated by an arrow; investigated members by WES and Sanger sequencing are with an asterisk; B) electropherograms of identified homozygous *WNT10B* mutation; two patients (II: 4 and II:6) present homozygous R115 and both parents are heterozygotes (I: 1 and I: 2); one health brother (II: 3) shows homozygous wild-type; C) schematic view of the *WNT10B* gene structure, protein domains, and localization of identified *WNT10B* mutations; the mutations reported were indicated with green frame and the mutation identified in this study was indicated with red frame