

OPEN ACCESS

Repository of the Max Delbrück Center for Molecular Medicine (MDC)
Berlin (Germany)

<http://edoc.mdc-berlin.de/14296/>

Erdheim-Chester disease and knee pain in a dialysis patient

Rademacher, S., Anagnostopoulos, J., Luft, F.C., Kettritz, R.

This is a pre-copyedited, author-produced PDF of an article accepted for publication in the *Clinical Kidney Journal* following peer review. The version of record: *Rademacher, S., Anagnostopoulos, J., Luft, F.C., Kettritz, R. Erdheim-Chester disease and knee pain in a dialysis patient. Clin Kidney J 7(4): 402-405, 2014.* is available online at: <http://dx.doi.org/10.1093/ckj/sfu031>

Oxford University Press ►

Clinic Report

Erdheim-Chester disease and knee pain in a dialysis patient

Sibylle Rademacher¹, Joannis Anagnostopoulos², Friedrich C. Luft³, and Ralph Kettritz^{1,3}

¹Department of Nephrology and Intensive Care Medicine, Virchow Klinikum, Charité Medical Faculty, Berlin, Germany

²Department of Pathology, Charité Medical Faculty, Berlin, Germany

³Experimental and Clinical Research Center, Max-Delbrück Center for Molecular Medicine and Charité Medical Faculty, Berlin, Germany

Correspondence: Ralph Kettritz; Email: Kettritz@charite.de

Abstract

Erdheim-Chester disease is a rare inflammatory condition characterized by a non-Langerhans' histiocytic infiltration, involving the skeleton, nervous system, viscera, retroperitoneum, and elsewhere. The aetiology is unknown. Positron-emission tomography shows areas of involvement. We managed a dialysis patient with knee pain; a bone marrow specimen showed typical CD68 positive, but CD1a negative cells. We initiated interferon- α therapy although other options remain open. In our patient, the simultaneous presence of secondary hyperparathyroidism with tumorous calcifications provided an interesting additional differential diagnostic possibility regarding skeletal pain.

Introduction

Bone pain in poorly controlled dialysis patients with secondary hyperparathyroidism and chronic hyperphosphatemia suggests the presence of parathyroid hormone-initiated osteitis fibrosa cystica. When tumorous metastatic calcifications are discovered matters seem

clear. Our investigations uncovered a rare disease that had been overlooked. As a result, we were introduced to the multifaceted clinical presentations of non-Langerhans cell histiocytosis, Erdheim-Chester disease (ECD) [1].

Case report

The 45 year-old continuous-ambulatory peritoneal dialysis patient was admitted because of generalized progressive weakness, lassitude, bilateral knee pain, and an elevated C-reactive protein (CRP). She was a recovered heroin addict receiving methadone and had been treated successfully for hepatitis C virus. She had undergone renal biopsy for diminished renal function and proteinuria earlier, which revealed arteriosclerosis and focal-sclerosing glomerulosclerosis. Dialysis commenced 3 years prior to admission. The patient's compliance to this treatment was suboptimal. She also reported that 7 years earlier she had undergone bone-marrow aspiration for unexplained anaemia and that a non-Langerhans cell (CD1a negative, CD68 positive) histiocytosis had been diagnosed. We were unable to obtain further medical records concerning that episode. The patient had observed a 3 kg weight loss, as well as a decrease in her daily urinary output. She was normotensive (130/90 mm Hg), had a regular pulse, clear lungs, a systolic murmur consistent with mitral regurgitation, no organomegaly, and moderate pedal oedema. A moveable infraclavicular 2-cm diameter mass was palpated. Routine laboratory values were unremarkable, save for a CRP 139 mg/dL, parathyroid hormone 275 ng/L, calcium 2.48 mmol/L and elevated phosphorus 2.87 mmol/L.

Roentgenogram of both knees revealed bilateral 3 cm soft-tissue calcifications, medial to the knee joints. Joint space was preserved and unremarkable (Figure 1A), while the hand films showed no evidence of hyperparathyroidism. We performed a biopsy of the subclavicular mass and found metastatic calcification, without histiocytic infiltration (not shown). We diagnosed tumorous soft-tissue calcifications (Figure 1A and 1B) related to

poorly controlled secondary parathyroidism and in the course of the hospitalization a 5/6 parathyroidectomy was performed [2]. Nonetheless, the nontypical knee pain that persisted and the history of histiocytosis puzzled us. A recent report in nephrology journal led us to conclude that Occam's razor is not always all that sharp [3]. The report concerns a woman with knee pain, polyuria, and bilateral hydronephrosis. Imaging of the knees and long bones in that patient showed diffuse irregular sclerotic changes involving the long bones. The hydronephrosis was caused by collagenous fibro-adipose tissue with lymphoplasma cells and histiocytic infiltration. The histiocytes were CD1a negative, but CD68 positive. We recognized the condition as ECD, a non-Langerhans cell histiocytosis.

Additional imaging of our patient revealed sclerotic changes of both proximal and distal femurs bilaterally (Figure 2A), whereas additional tumorous calcifications are also visible. We performed whole-body positron-emission tomography (CT-PET) scanning with ¹⁸F deoxyglucose (Figure 2B). The study revealed osteolytic and osteoplastic changes with increased activity at numerous sites including proximal and distal long bones, clavicles, sacrum, acetabula and glenoids. Note was also made of tumorous calcifications at various sites. We performed a bone-marrow biopsy (Figure 3A). That study showed, in addition to changes of secondary hyperparathyroidism (not shown) intense infiltration with lipid-laden histiocytic cells. The cells were CD1a negative, but CD68 positive (Figure 3B). Long-term high-dose interferon- α is considered a treatment of choice for ECD and was initiated by our consultants [4]. We are currently observing our patient, who seems to be improving.

Discussion

ECD is a rare non-Langerhans cell histiocytosis characterized by infiltration of foamy CD68 positive, but CD1a negative macrophages and fibro-inflammatory lesions in various

organs, including retroperitoneal sites, periureteral areas, as recently reported by Kang et al [3], and bones. The origin and pathophysiology, of ECD are unknown. Cavalli et al [1] recently reviewed the topic and identified 259 ECD patients. They predominantly presented with skeletal symptoms, diabetes insipidus, neurological, and constitutional manifestations. The authors observed that ECD presented most frequently with skeletal symptoms. Bone involvement, both silent and symptomatic, was present in almost all patients. Roentgenographic findings were commonly symmetric diaphyseal osteosclerosis with contrast-material uptake in long bones by scintigraphy, as we observed in our PET-CT studies. The histology invariably showed a xanthogranulomatous infiltrate composed by foamy histiocytes accompanied by fibrosis. Immunohistochemical studies revealed that the infiltrating histiocytes were positive for CD68, but negative for the dendritic cell markers CD1a.

Cavalli et al [1] also emphasized that constitutional symptoms represented the initial complaint of ECD patients in 20% of cases, as was the case here. Our patient's CRP has since decreased. Although an interferon- α therapy has been favoured [4], other options are available. Aubert et al [5] reported a refractory ECD patient who was given the interleukin-1 receptor antagonist, anakinra. After 1 year of treatment, the CT-PET studies revealed an outstanding response of the skeletal involvement with clearly lower and smaller hyper-metabolism images in that patient. Should interferon- α and anakinra fail, we were interested to learn about another feature of ECD that could also have mechanistic implications. Haroche et al [6] reported on a dramatic efficacy of vemurafenib in three refractory ECD patients. Vemurafenib has been employed in the treatment of patients with malignant melanoma, whose tumours feature *BRAF* V600E mutations. *BRAF* encodes the protein B-Raf, a serine/threonine-protein kinase. Vemurafenib is approved for treatment of late-stage

melanoma with the V600E mutation. Haroche et al [6] point out that 57% of patients with Langerhans cell histiocytosis and 54% of ECD patients harbour the *BRAF* V600E mutation in their aberrant histiocytes. Should our patient not respond to our current therapy, we would perform genotyping for V600E.

William of Ockham was an English Franciscan friar, scholastic philosopher, and theologian. His idea, termed “Occam’s razor” states that when explaining a phenomenon one should always opt for the fewest possible causes, factors, or variables, preferably only one. We initially assumed that secondary hyperparathyroidism explained our patient’s pain. Sometimes clinicians must veer from Occam’s path and accept the possibility that both “lice and fleas” are present. Neither do we believe that tumorous calcifications and ECD are associated. Nor do we have any evidence that ECD participated in our patient’s chronic renal failure.

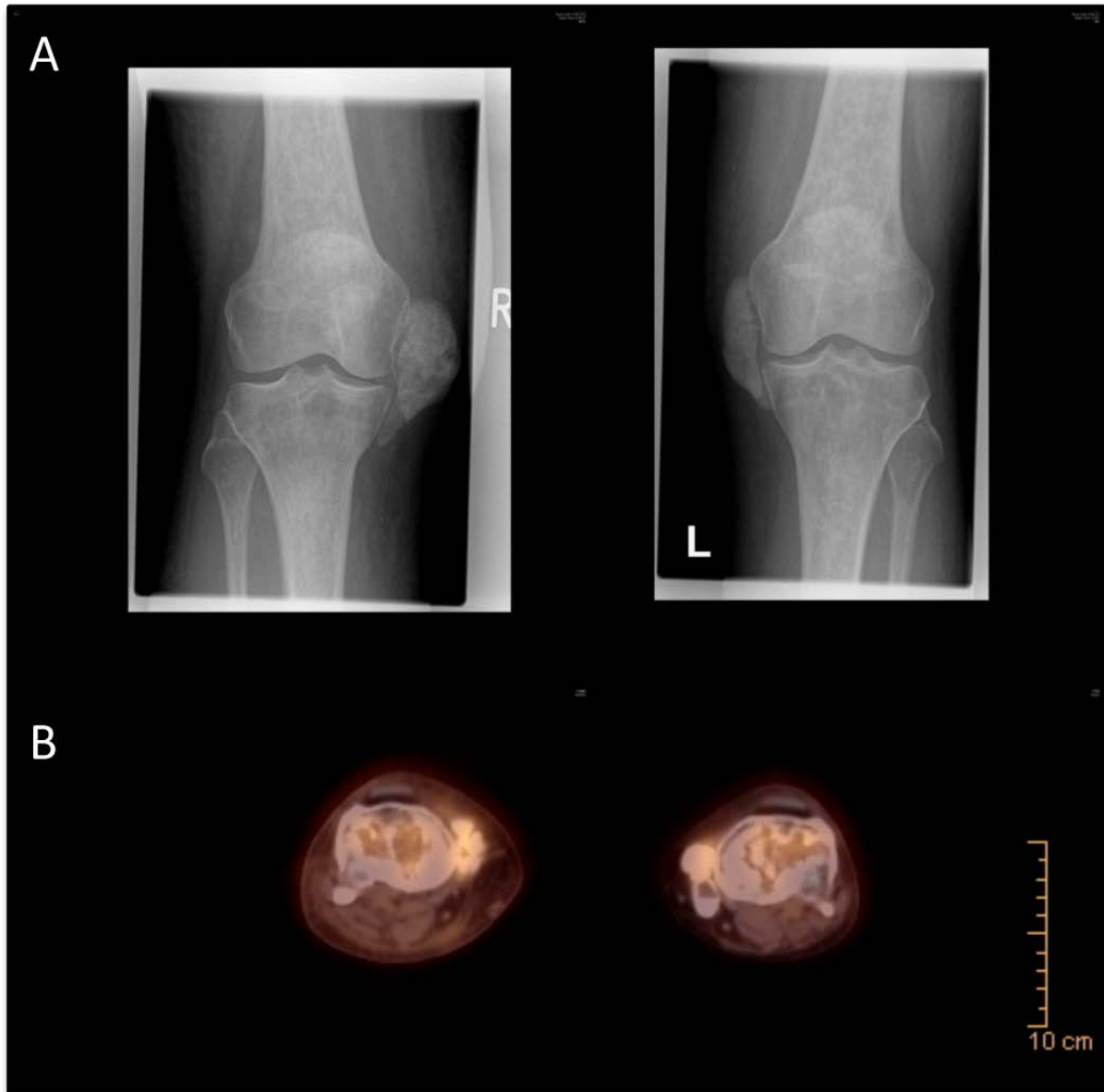


Figure 1. Roentgenograms of both knees (1A). Striking are the medial tumorous calcifications adjacent to the knee joints bilaterally. No changes consistent with calcium pyrophosphate deposition could be found. (1B). Computerized positron emission tomography (PET-CT) with contrast of knee joints. Markedly enhanced glucose metabolism localized to soft-tissue excrescences medial to both knees, although enhancement is also evident in the proximal tibia bilaterally.

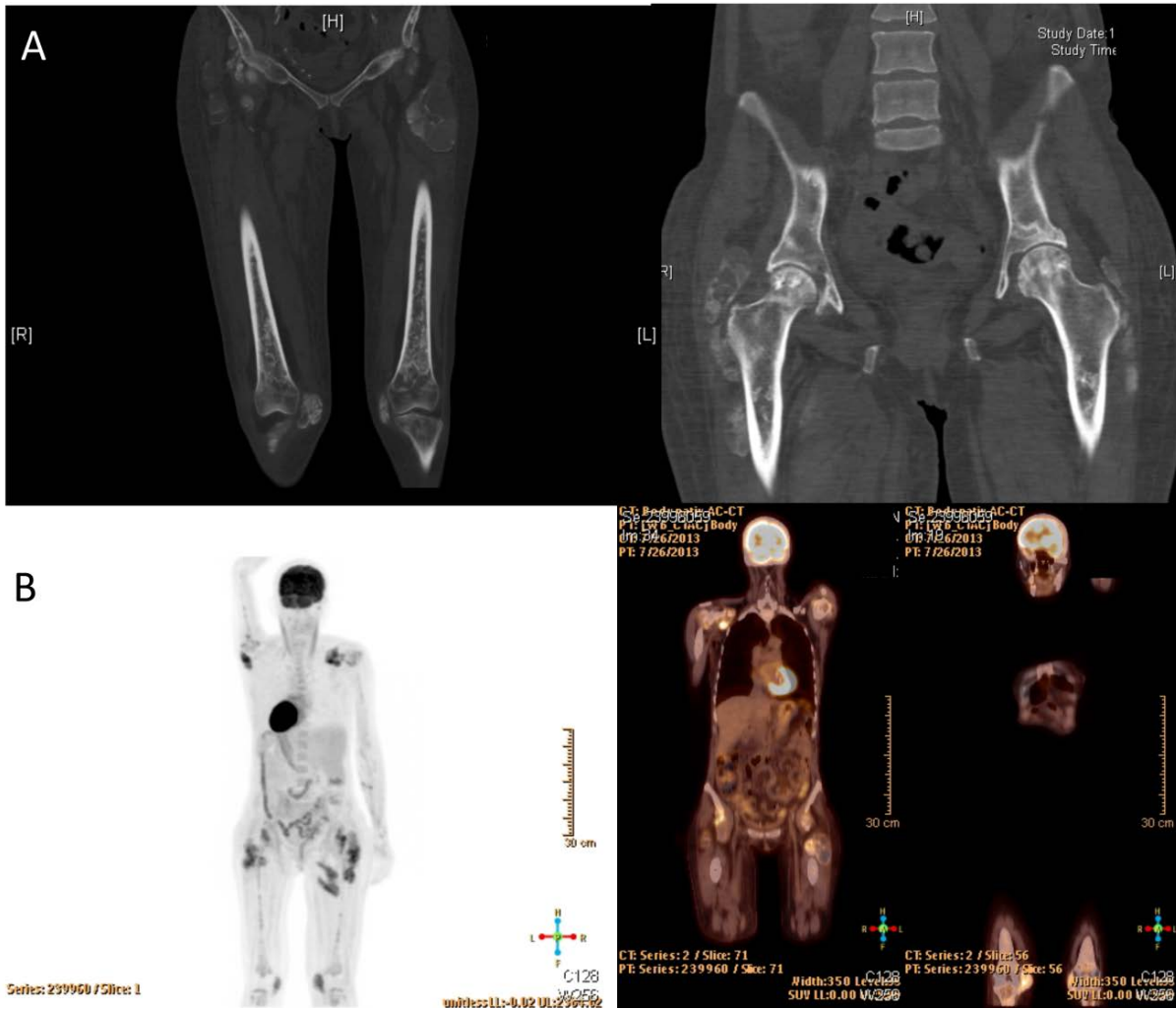


Figure 2 A. Sclerosis of both distal and proximal femurs is evident. Note is also made of the tumorous soft-tissue calcification adjacent to both trochanters and at other sites. Figure 2B. Total-body PET-CT shows markedly increased glucose metabolism at numerous skeletal sites, particularly proximal and distal long bones and pelvis.

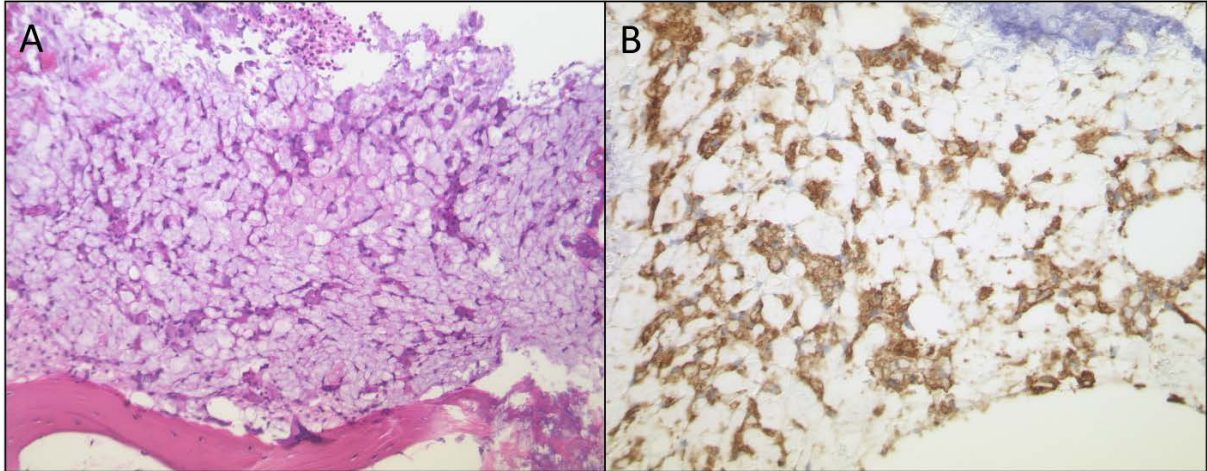


Figure 3A. Bone marrow biopsy shows marked infiltration by lipid-laden cells. Figure 3B. The cells stained for CD68 (brown coloration), but not for CD1a.

Funding and disclosures

This work received no funding. There are no interest conflicts.

References

1. Cavalli G, Guglielmi B, Berti A, Campochiaro C, Sabbadini MG, Dagna L. The multifaceted clinical presentations and manifestations of Erdheim-Chester disease: comprehensive review of the literature and of 10 new cases. *Ann Rheum Dis* 2013;72:1691-5.
2. Floege J. When man turns to stone: Extrasosseous calcification in uremic patients. *Kidney Int* 2004;65:2447-62.
3. Kang JH, Choi YD, Kim CS *et al.* Obstructive uropathy from Erdheim-Chester disease. *Kidney Int* 2013;83:975-976.
4. Hervier B, Arnaud L, Charlotte F *et al.* Treatment of Erdheim-Chester disease with long-term high-dose interferon- α . *Semin Arthritis Rheum.* 2012;41:907-13.
5. Aubert O, Aouba A, Deshayes S, Georgin-Lavialle S, Rieu P, Hermine O. Favorable radiological outcome of skeletal Erdheim-Chester disease involvement with anakinra. *Joint Bone Spine.* 2013;80:206-7.
6. Haroche J, Cohen-Aubart F, Emile JF *et al.* Dramatic efficacy of vemurafenib in both multisystemic and refractory Erdheim-Chester disease and Langerhans cell histiocytosis harboring the *BRAF* V600E mutation. *Blood* 2013;121:1495-500.